

An unusual case of endometriosis deposits in the urinary bladder diagnosed by transvaginal ultrasound.

J. Collings Advanced Practitioner Sonographer, E.R Smith Superintendent Sonographer, Torbay Hospital ,Torquay, Devon.

Introduction

This poster presents an unusual case of deeper infiltrating endometriosis (DIE) affecting the bladder wall which is rare and the exact cause is unknown. Endometriosis is a common benign gynaecological disease characterised by the presence of ectopic endometrial tissue outside the uterus. It is a well known fact that endometriosis most commonly affects such organs as the ovaries, utero-sacral ligaments, uterine tubes, pouch of Douglas and rectum. Ureters are sometimes stenosed by the growth of endometriotic tissue around them. The bladder however, is an infrequent site of endometriosis and fewer than 200 cases of bladder endometriosis have been described in the literature (Mettler et al., 2008). The use of high detail transvaginal ultrasound in the sub-fertile woman is a crucial part of their work up during fertility investigations within the modern gynaecology department.

Case report

A 34 year old null gravida patient attended for a routine 'baseline scan for fertility investigations' ultrasound examination. The woman had been trying to conceive for two years with unprotected intercourse. BMI and blood hormones were normal. There was a history of painful periods that were tolerable, some dysuria and one episode of haematuria.

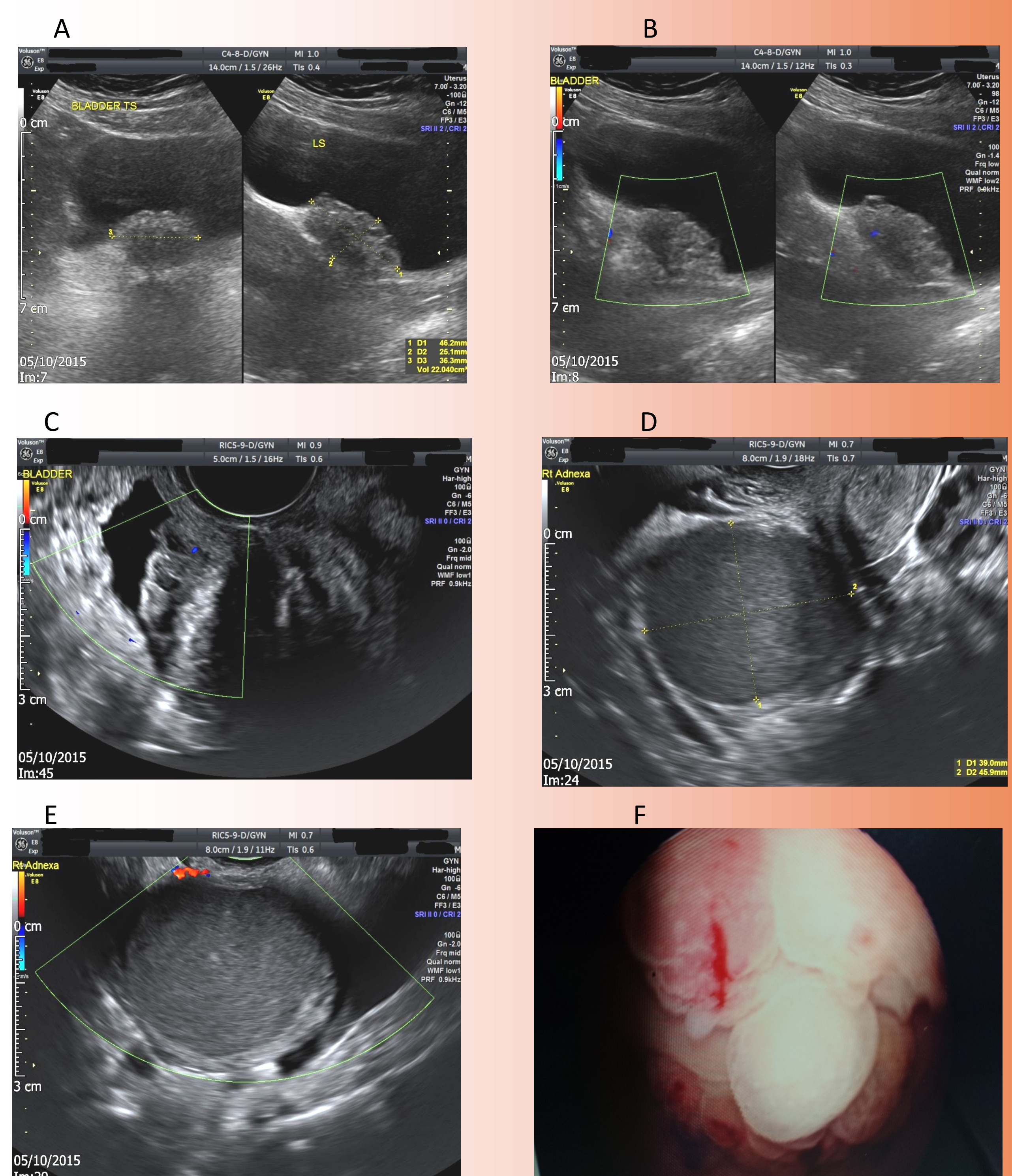
The transabdominal pelvic scan shows an irregular, solid mass lying on the posterior bladder wall measuring 46 x 36 x 25mm (Images A and B). Additional detail with transvaginal scan shows cystic areas and a trace of internal vascularity (see image C).

The right ovary contained a 49mm endometrioma, (*this was confirmed at laparoscopy*) (see image D and E). The anteverted uterus and left ovary appeared normal.

Immediate Urology referral was made and cystoscopy showed a large endometriotic deposit within the trigone area of the bladder with elevation of both ureteric orifices. A transurethral resection of the bladder tumour (TURBT) was performed (image F).

Histology showed macroscopically a mass weighing 5g that was embedded in all three layers of the bladder wall. Microscopically there were multiple foci of endometriosis with no evidence of malignancy.

At laparoscopy there was significant endometriosis particularly along the uterosacral ligaments, with a large thick deposit of the endometriosis in the bladder anterior to the uterus and densely adherent to the lower third of the uterus along its full width, reducing forward mobility of the uterus as a result. The right ovarian endometrioma was ablated and then excised. The large bowel adhesions were adhesiolysed and all visible endometriosis were diathermied.



Discussion

Endometriosis is a common gynaecological condition affecting millions of women worldwide. Estimates of prevalence vary widely but up to 15% of women in their reproductive years may be affected (Said and Azzam 2014). The penetration of the endometriosis can vary within two forms; superficial endometriosis is found on the outer surface of the bladder and deeper endometriosis is found on the inside of the bladder lining or wall, this can cause a nodule, which can also affect the ureters. Deep infiltrating endometriosis (DIE) is presented as a disease with high recurrence risk. Bladder DIE is the most frequent location of cases of urinary endometriosis, and not all DIE lesions give rise to symptoms. (Chapron, C. et al 2010). Transvaginal ultrasound is regarded the most useful imaging method for the prediction of endometriosis, independently or in combination with soft markers (ovaries not at the same level, high left ovary, ovarian fixation to uterus, tender ultrasound, ovarian fixation to iliac vessels and non visualization of left ovary), especially when there might be visible signs of solid/abnormal shaped deposits or cystic masses. (Said and Azzam 2014)

Conclusion

Ultrasound of the pelvis is the primary method of imaging women with pelvic pain and knowledge and confidence scanning the bladder when a lesion is seen should be considered part of the test. Trabeculation of the empty bladder on TV scanning can mislead the practitioner but will give better detail of larger lesions if scanned carefully. Endometriosis can occur in the form of superficial and deep implants on the bladder wall intrinsically or extrinsically. Diagnostic laparoscopy remains the reference standard for diagnosing pelvic endometriosis. More recently, however, detailed transvaginal ultrasound looking specifically for endometriotic lesions in correlation with the sites of pain has been quite effective in detecting the disease, without the need for MRI. Ultrasound is much more cost effective than MRI and has a high level of patient acceptance. Studies have shown that ultrasound is at least as sensitive and specific as MRI in detecting deep implants of endometriosis and is the first imaging examination of choice in patients suspected of having endometriosis. (Benacerrag, and Groszmann, 2012).

References

1. Benacerraf, B. and Groszmann, Y. (2012). *Sonography should be the first imaging examination done to evaluate patients with suspected endometriosis*. Journal of Ultrasound in Medicine. Vol. 31 no. 4 PP 651-195.
2. Chapron, C., Bourret, A., Chopin, N., Dousset, B., Leconte, M., Amsellem-Ouazana. D., De Ziegler, D., Borghese, B. (2010). *Surgery for bladder endometriosis: long-term results and concomitant management of associated posterior deep lesions*. Human Reproduction. Vol. 25, no. 4 PP 884-889.
3. Mettler, L. Gaikwad, V. Riebe, B. Schollmeyer, T. (2008) *Bladder endometriosis: Possibility of treatment by laparoscopy*. Journal of the Society of Laparo-endoscopic Surgeons. April—June 12(2) 162-165
4. Said, T. H., and Azzam, A. Z., (2014). *Prediction of endometriosis by transvaginal ultrasound in reproductive age women with normal ovarian volume*. Middle East Fertility Society Journal. Vol. 19. 3. September 2014, Pages 197–207