

Evaluating the impact of best practice diagnostic guidelines implementation: a retrospective review of ultrasound findings in women aged 35-39 years attending a diagnostic breast clinic.

Imelda Marshall¹, Anne-Marie Culpan²

¹Bradford Teaching Hospitals NHS Foundation Trust, ²University of Leeds.

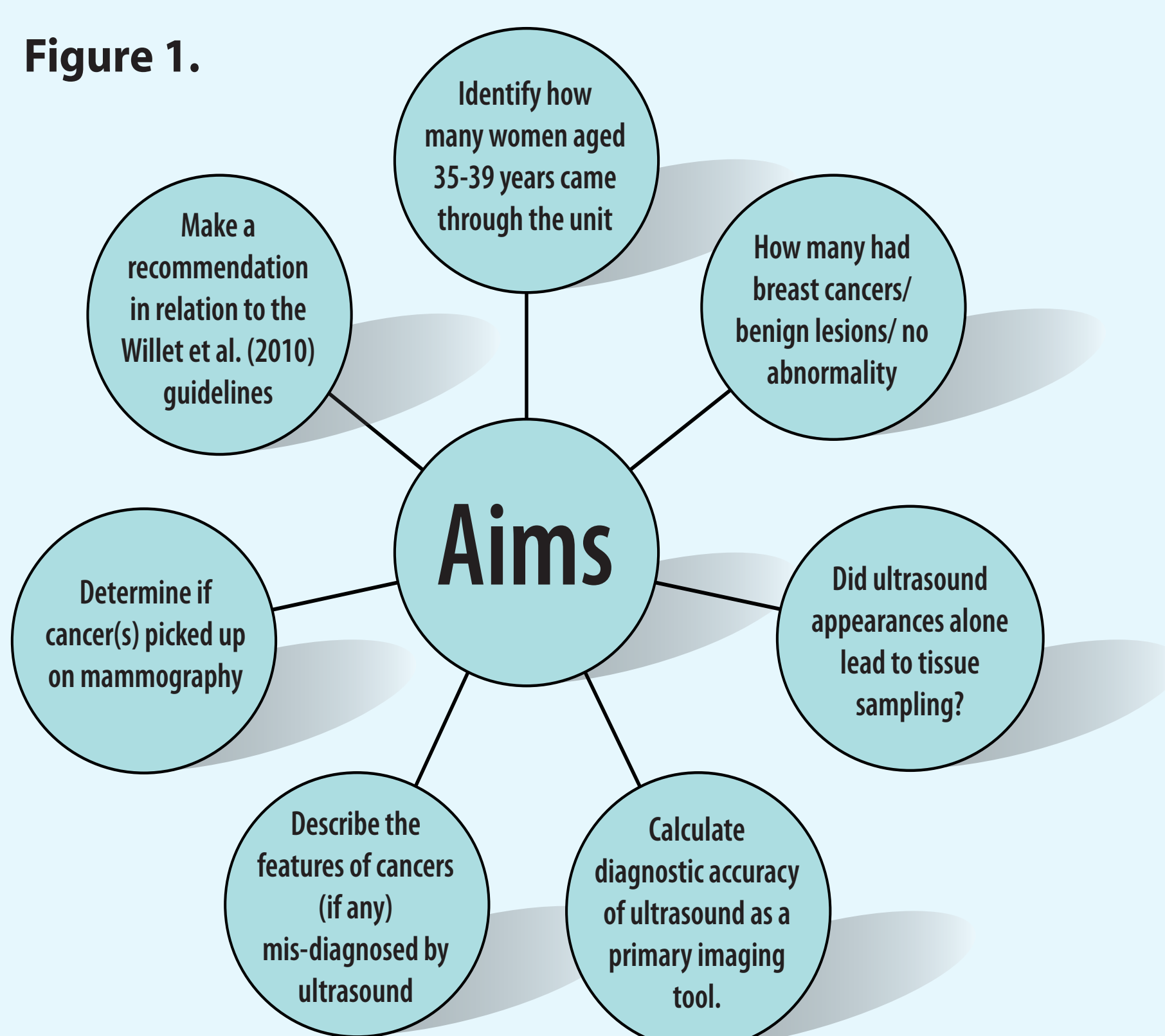
Introduction

In 2010 Willet et al. produced national guidelines for the management of patients attending a symptomatic breast clinic. This led to a significant change in imaging practice, particularly for women aged 35-39 years who would no longer be offered a mammogram in addition to ultrasound in the initial assessment of breast disease - this cohort of patients would now have ultrasound alone as their primary imaging tool.

Aims

The overall focus of the study was to evaluate if the best practice guidelines for patients presenting with breast symptoms were meeting local service need in that all cancers in women in the 35-39 year age range were detected using ultrasound as a primary imaging tool. The aims of the study are illustrated in Figure 1.

Figure 1.



Methods

A retrospective audit was conducted using Mistry et al. (2013) as the audit standard. Data was gathered from three databases (CRIS, local cancer database, regional cancer database) to generate a list of all women aged from 35-39 years attending the breast clinic from the 1st January 2012- 31st July 2015.

Data recorded included clinical presentation, P/M/U classification, follow up and final histology findings.

Results

1141 women met the study inclusion criteria. 17 breast cancers were detected (prevalence 1.5%). Malignancy was suggested on the basis of ultrasound appearances in 23 (false positive) and 14 (true positive) cases (Figure 2). Three malignancies (false negative) cases were classified as normal (n=1) or benign (n=2) at ultrasound. Two of these malignant cases were diagnosed at the time of presentation on the basis of mammography performed in accordance with other guidelines (positive family history and unexplained deep vein thrombosis). One case with multi-focal cancer was diagnosed at re-presentation after an 8 month interval (Figures 3-8). In this study the sensitivity, specificity and overall diagnostic accuracy of target ultrasound scanning were 82.35%, 97.95% and 97.77% respectively.

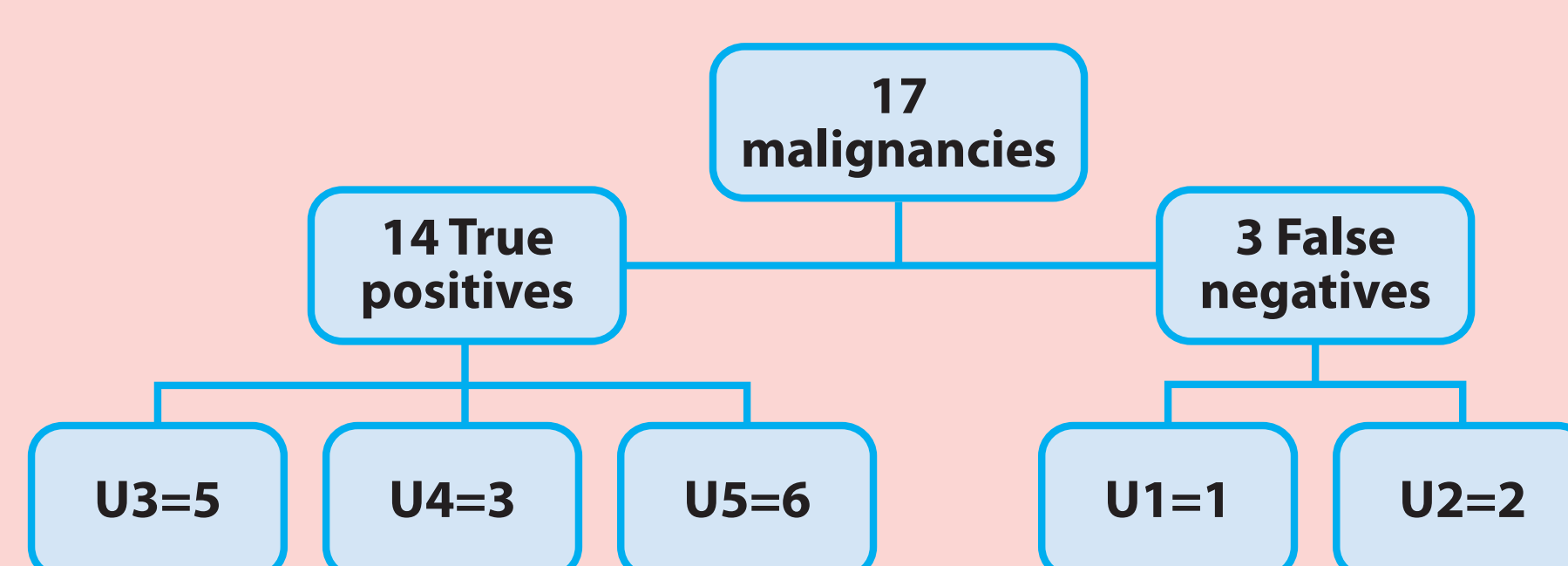


Figure 2. Ultrasound classifications for the malignancies

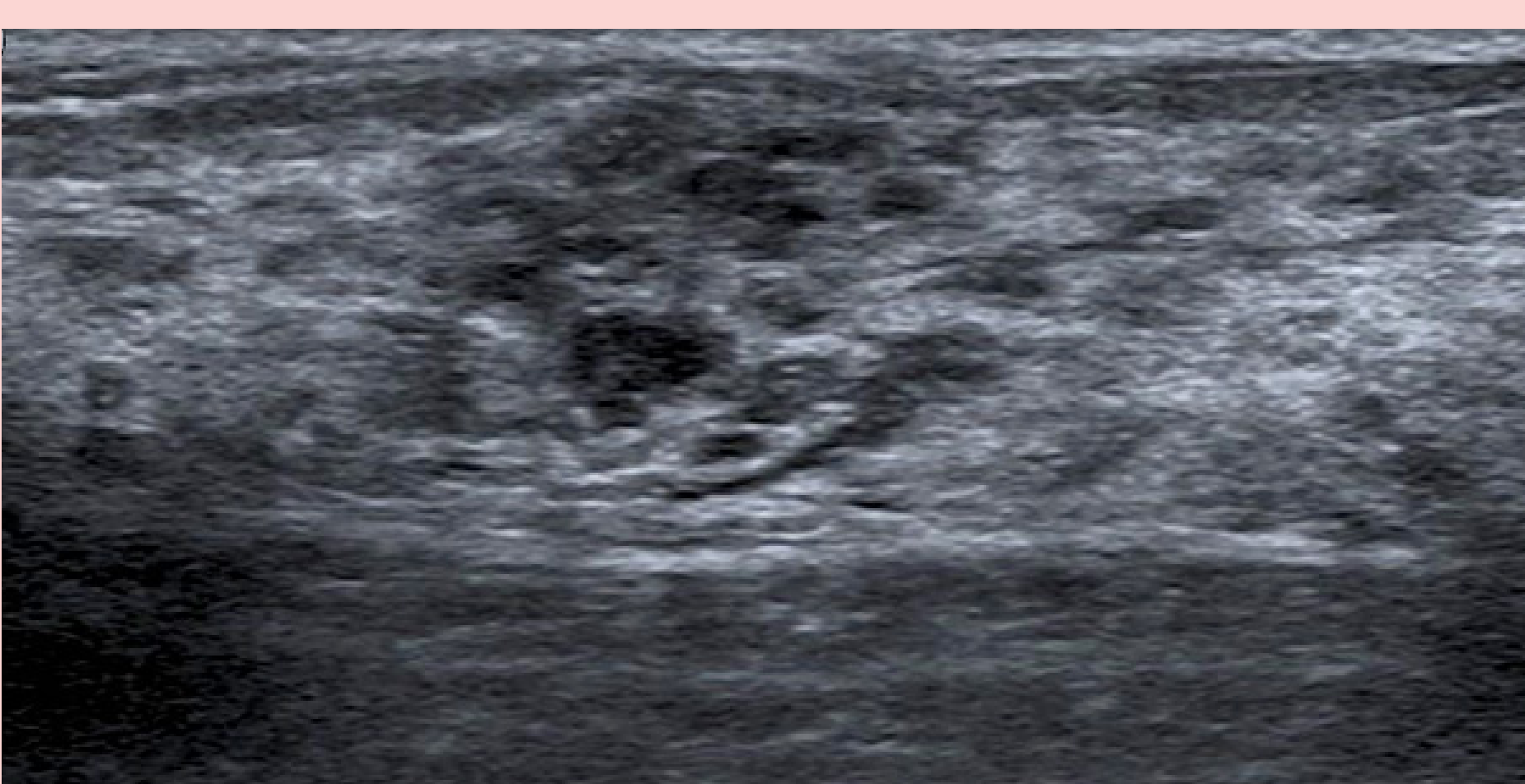


Figure 3. Ultrasound examination- reported as focal fibrocystic change (U2). Palpable lump at 10 o'clock.

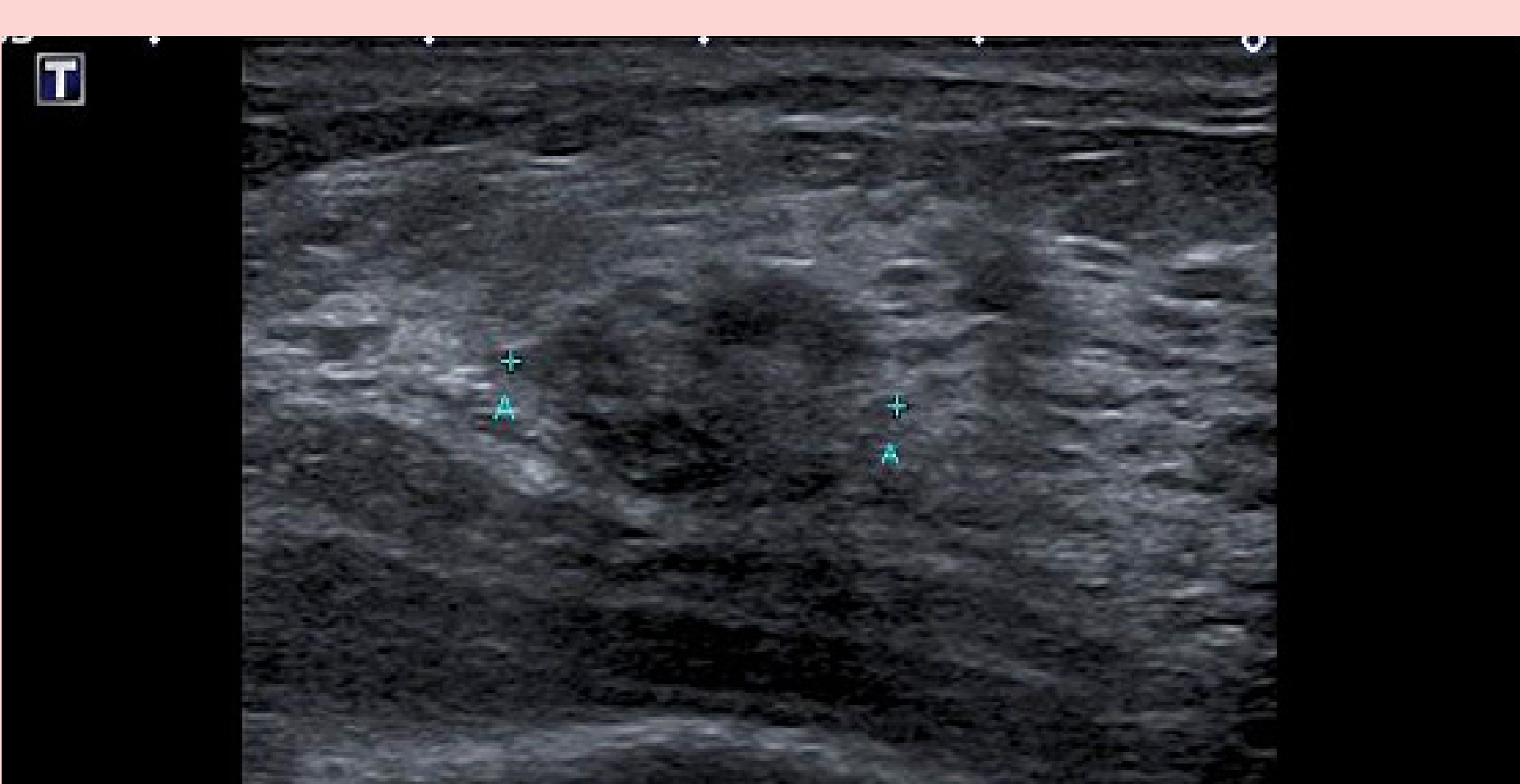


Figure 4. Ultrasound examination on re-presentation 8 months later. This was classified as U3.

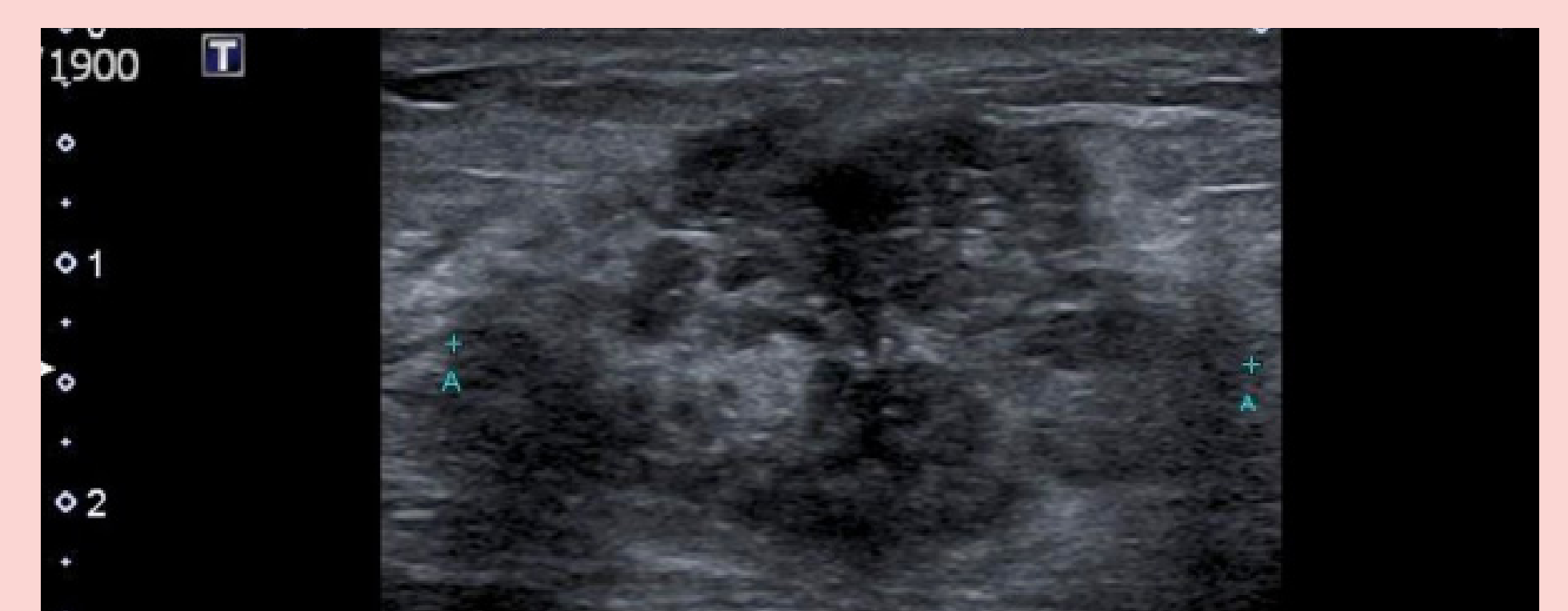
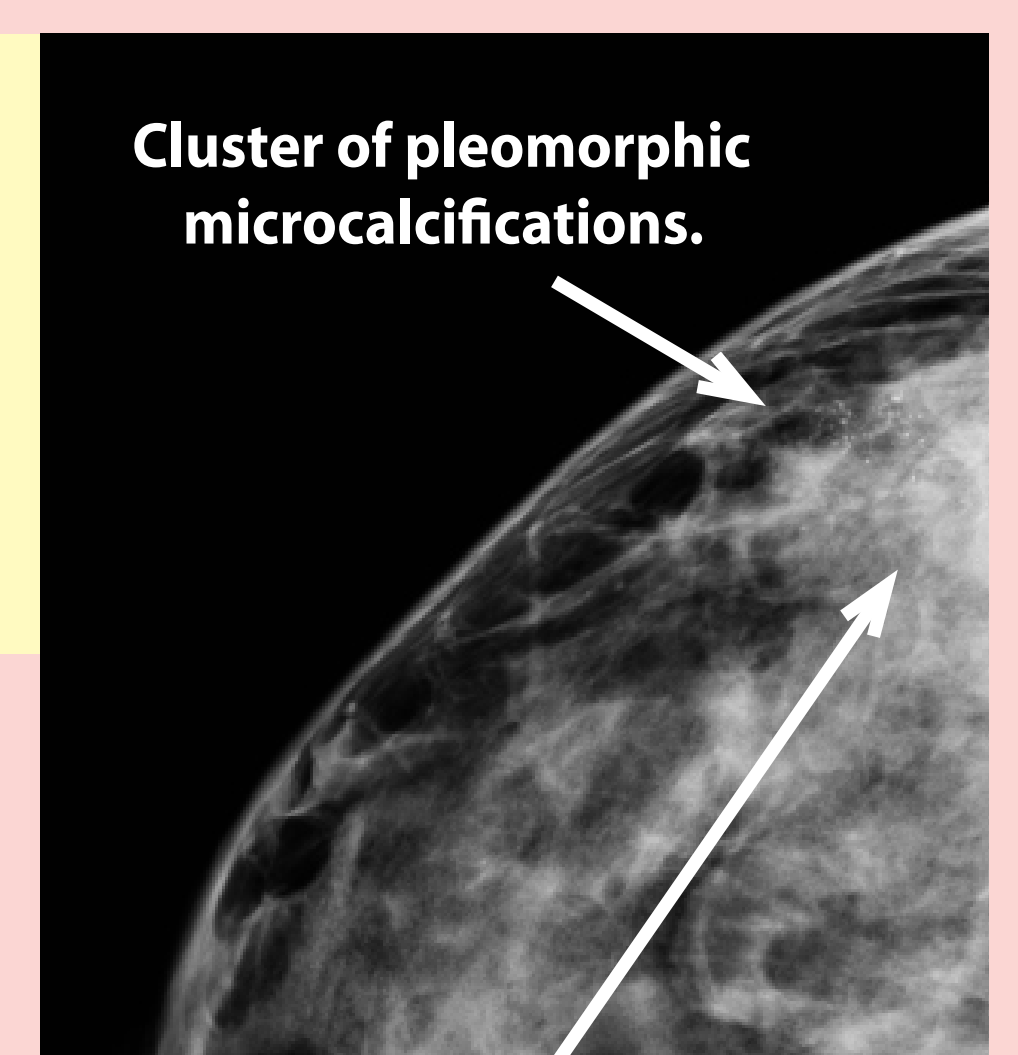


Figure 5. Ultrasound examination, further new palpable area at 9 o'clock, classified as U4.

Figure 6.

Cranio-caudal projection of the symptomatic breast, showing pleomorphic calcifications in the outer breast.



Cluster of pleomorphic microcalcifications.

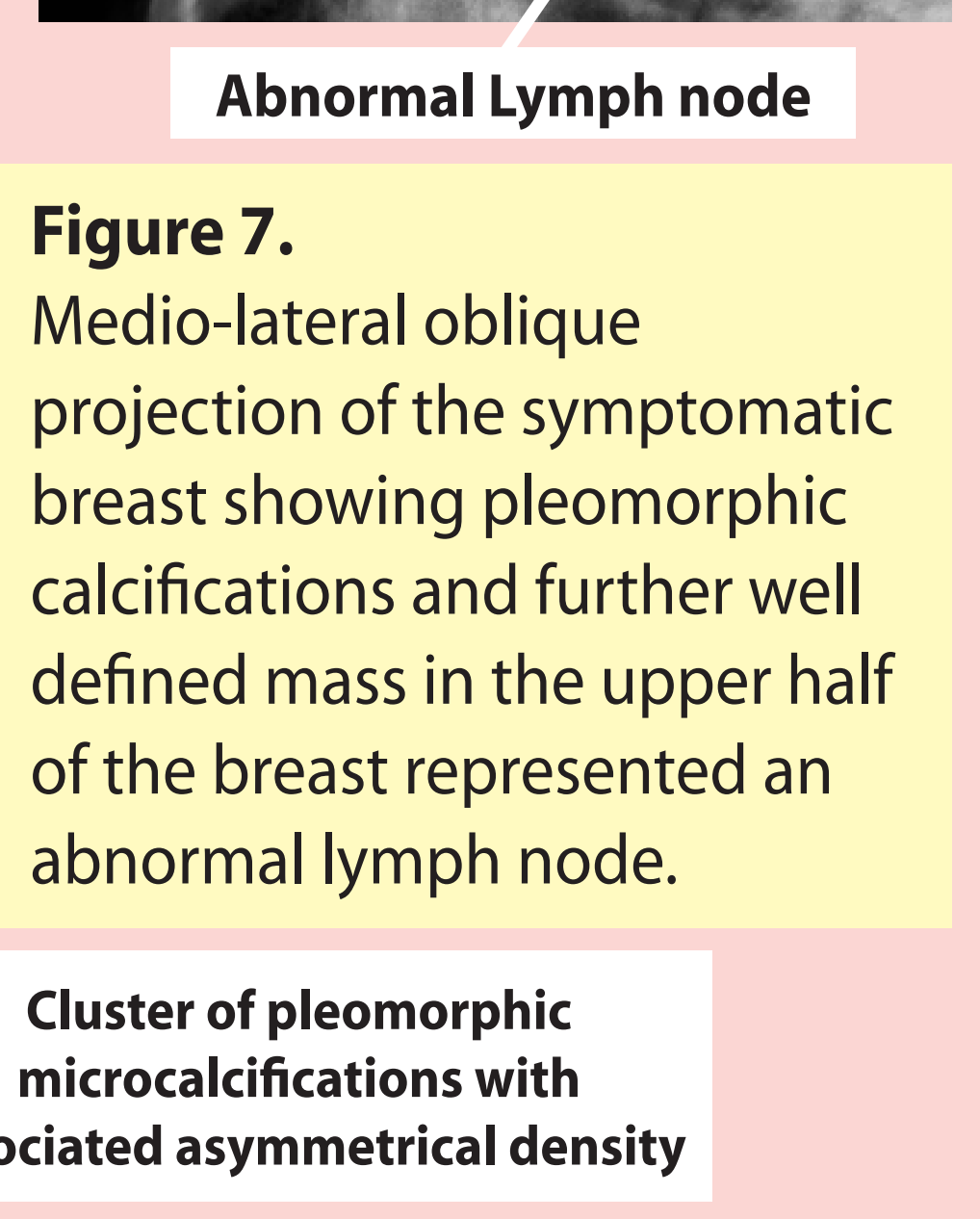
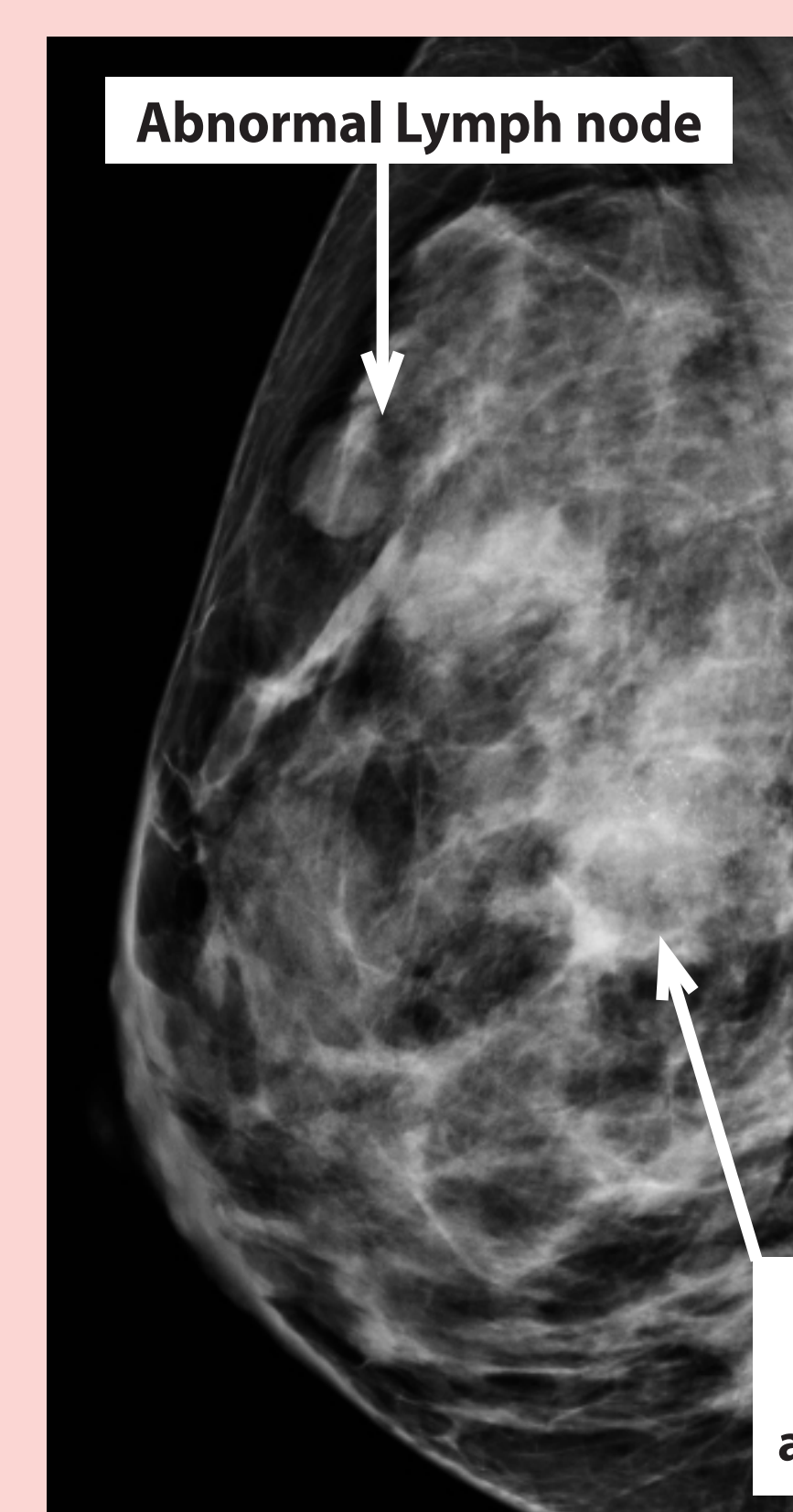


Figure 7. Medio-lateral oblique projection of the symptomatic breast showing pleomorphic calcifications and further well defined mass in the upper half of the breast represented as an abnormal lymph node.

Cluster of pleomorphic microcalcifications with associated asymmetrical density

Conclusion

Ultrasound examinations targeted to the site of a presenting focal abnormality in women aged 35 – 39 years will fail to detect a small number of malignancies due to overlap in benign and malignant appearances and due to the low, but finite, prevalence of asymptomatic cancer elsewhere in the breasts in this population.

References

- Mistry S G. Barnes N. (2013) Will adherence to new guidance lead to missed cancer diagnoses? Evaluation of limiting symptomatic mammograms to over forties. The breast Journal. Vol 19. No 2. Pp142-148.
- Willet A M. Mitchell M J. Lee M J R. (2010) Best Practice diagnostic guidelines for patients presenting with breast symptoms. Department of health. Breast Cancer Breakthrough.