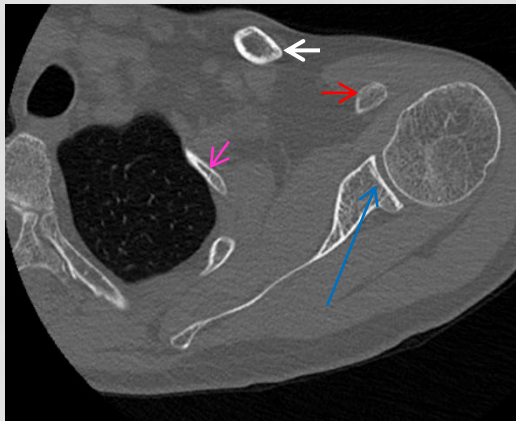
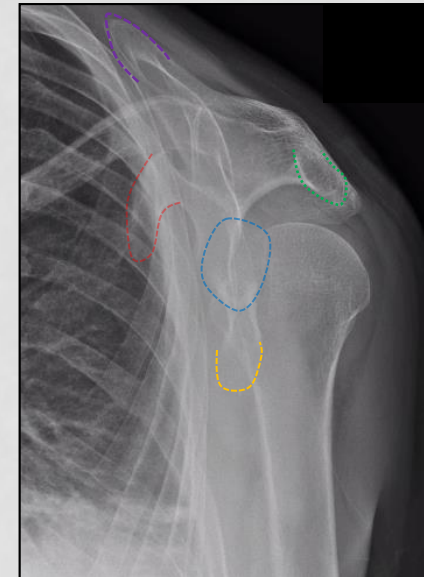
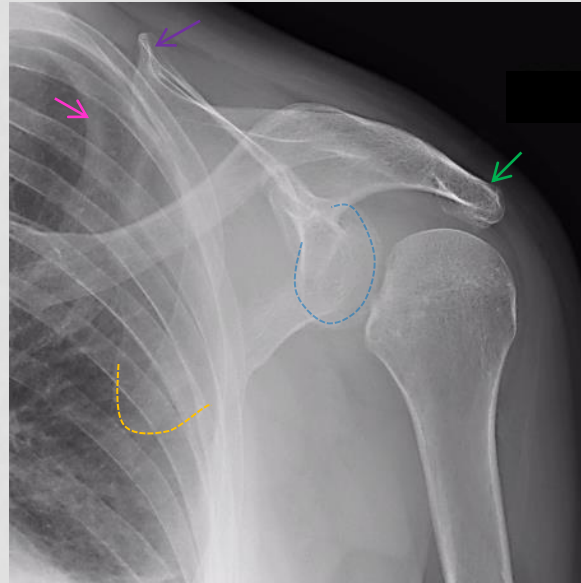
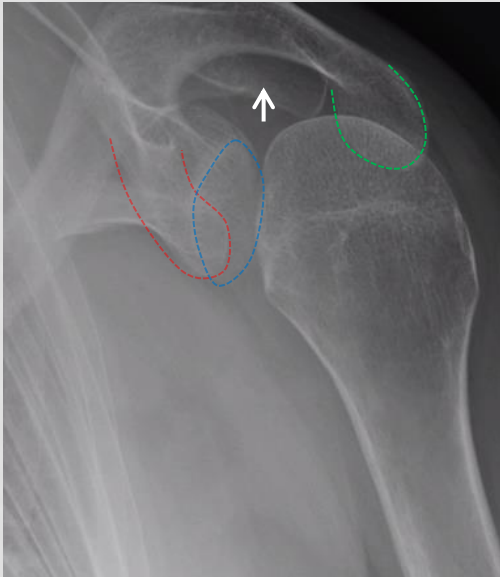


INTERESTING CASE FILES EDITION 4

Test yourself and others!



- 1) Use the colour key to identify the anatomical bony parts seen on shoulder imaging
- 2) What is your interpretation of the X-ray appearances (*note the CT was taken at a different time to the XR's*)
- 3) Is there anything else of note? (Hint- you may find the AP view most helpful)