
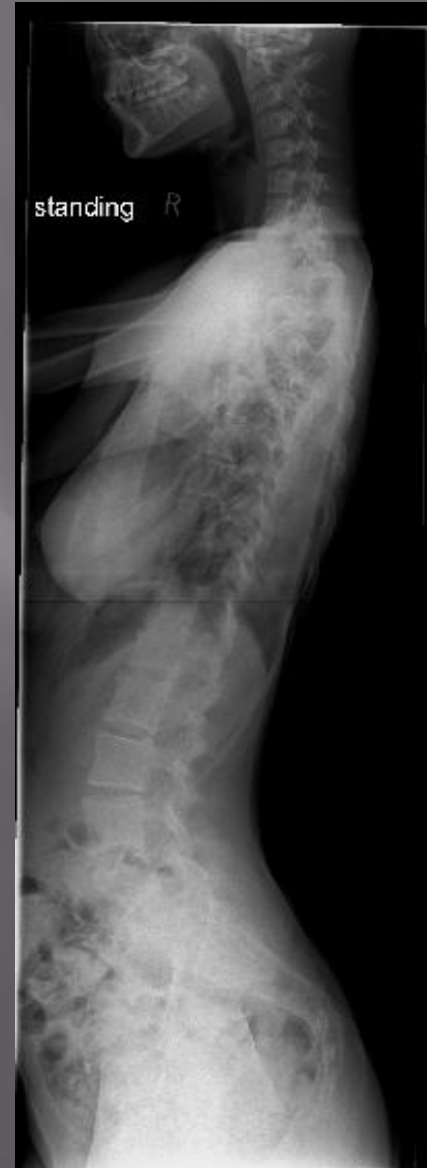
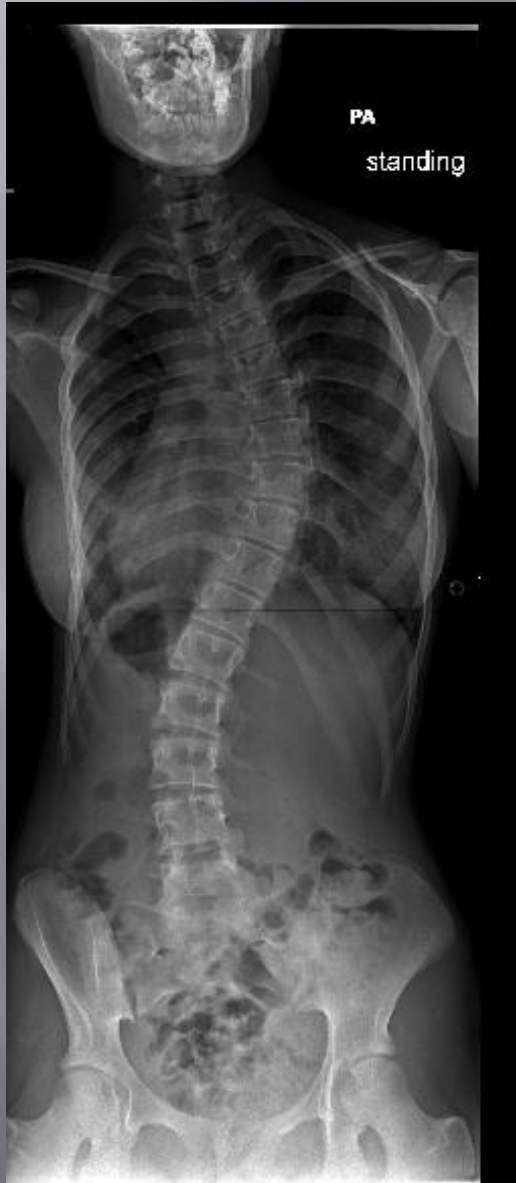

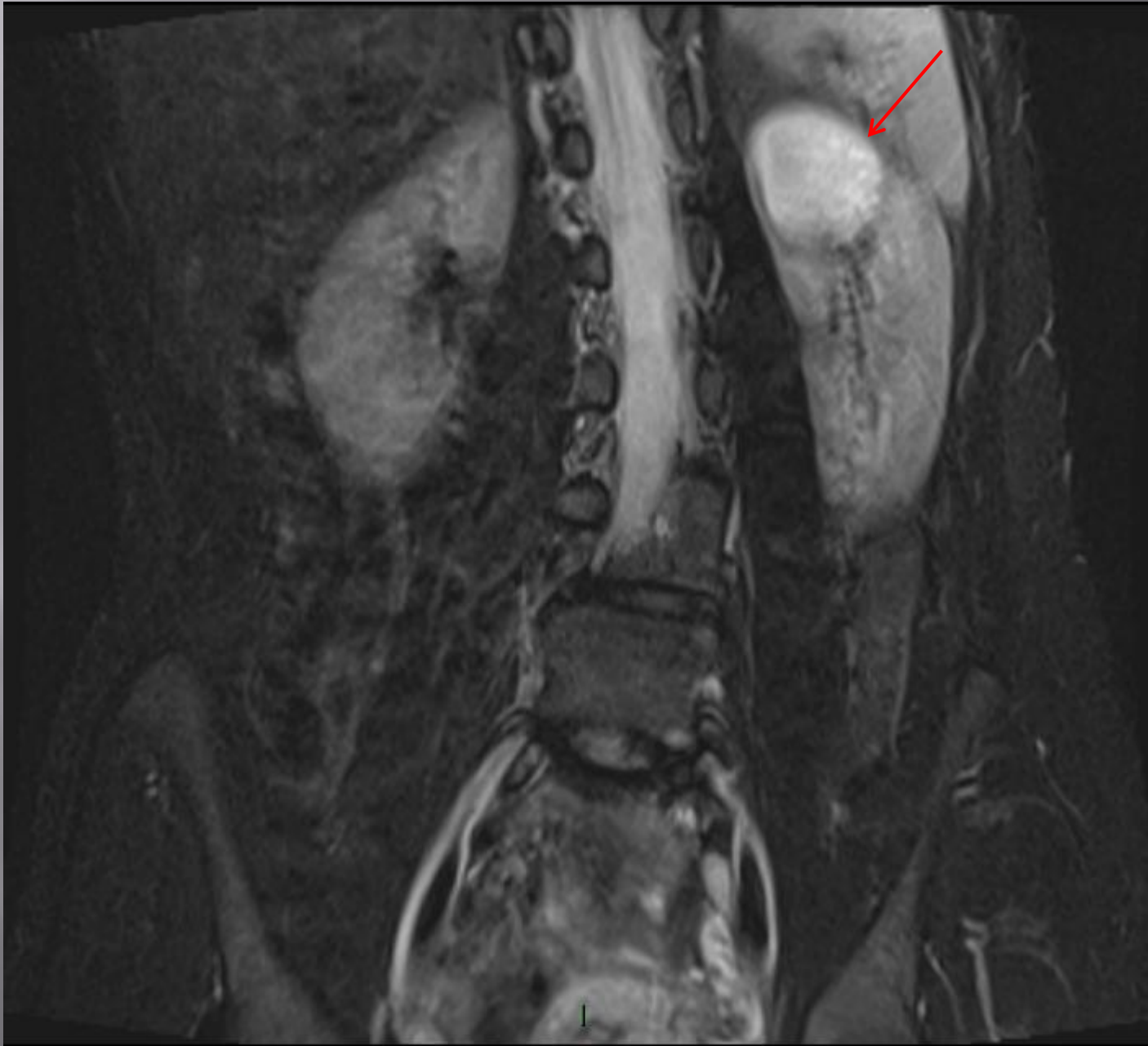
Tales
of the
Unexpected

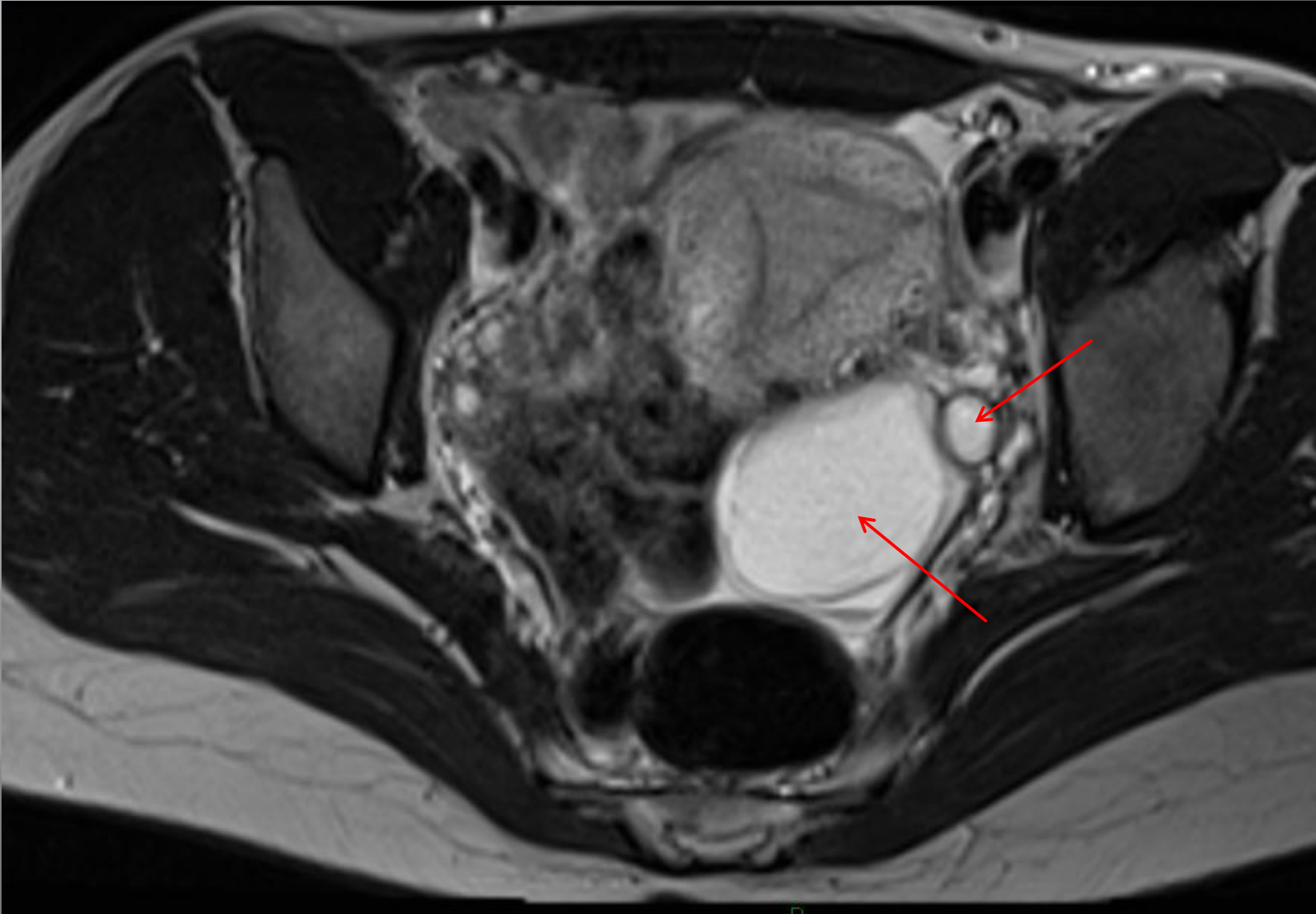
Jen Matrundola RHSC, Edinburgh

Scoliosis X-rays

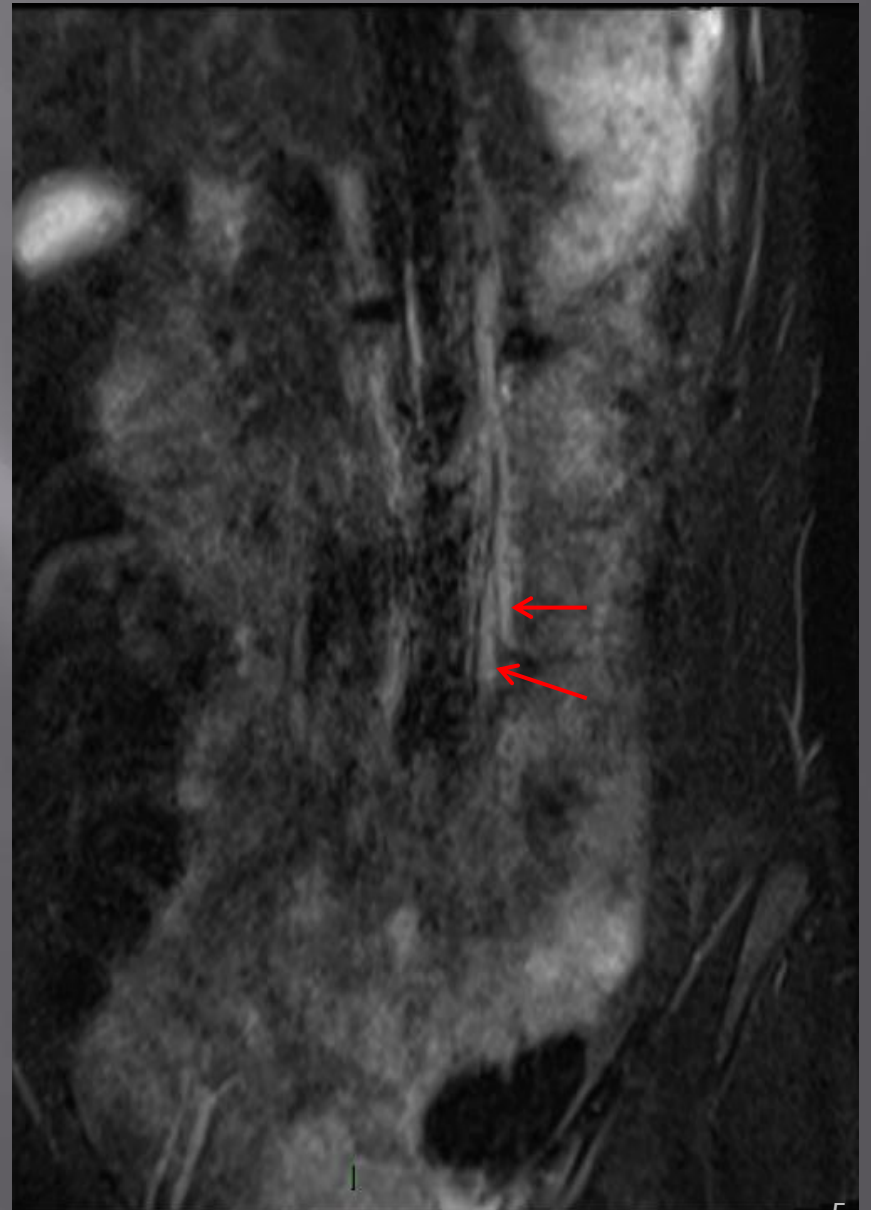
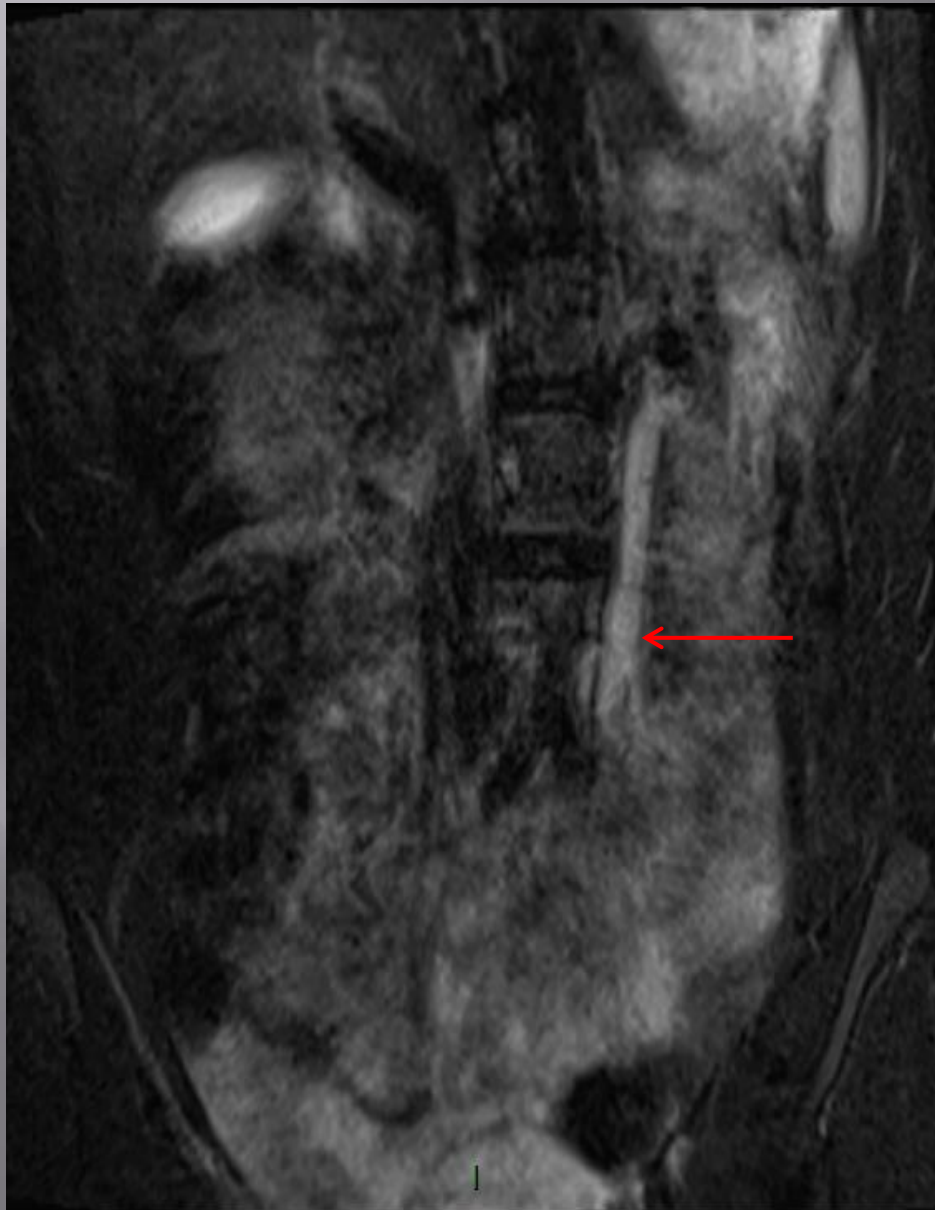


Scoliosis patient with incidental renal cyst

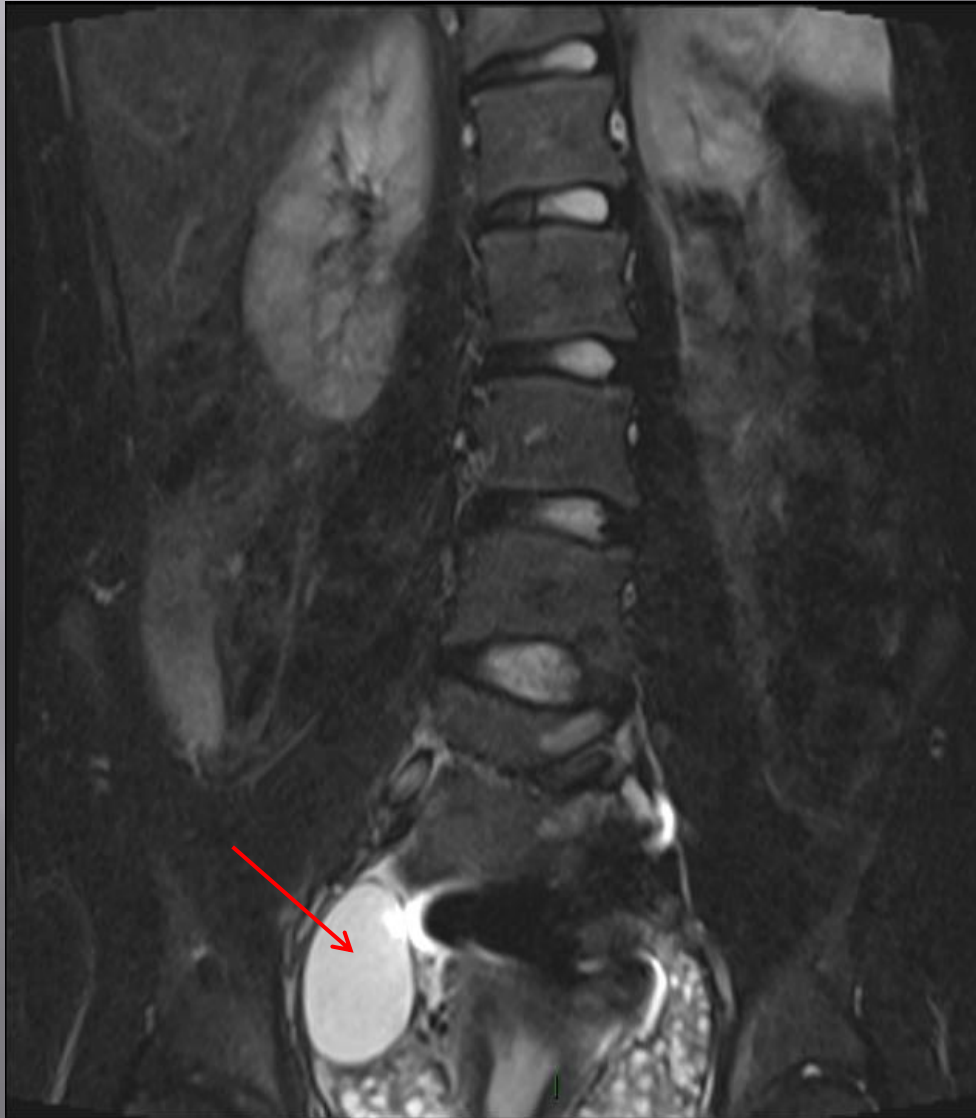




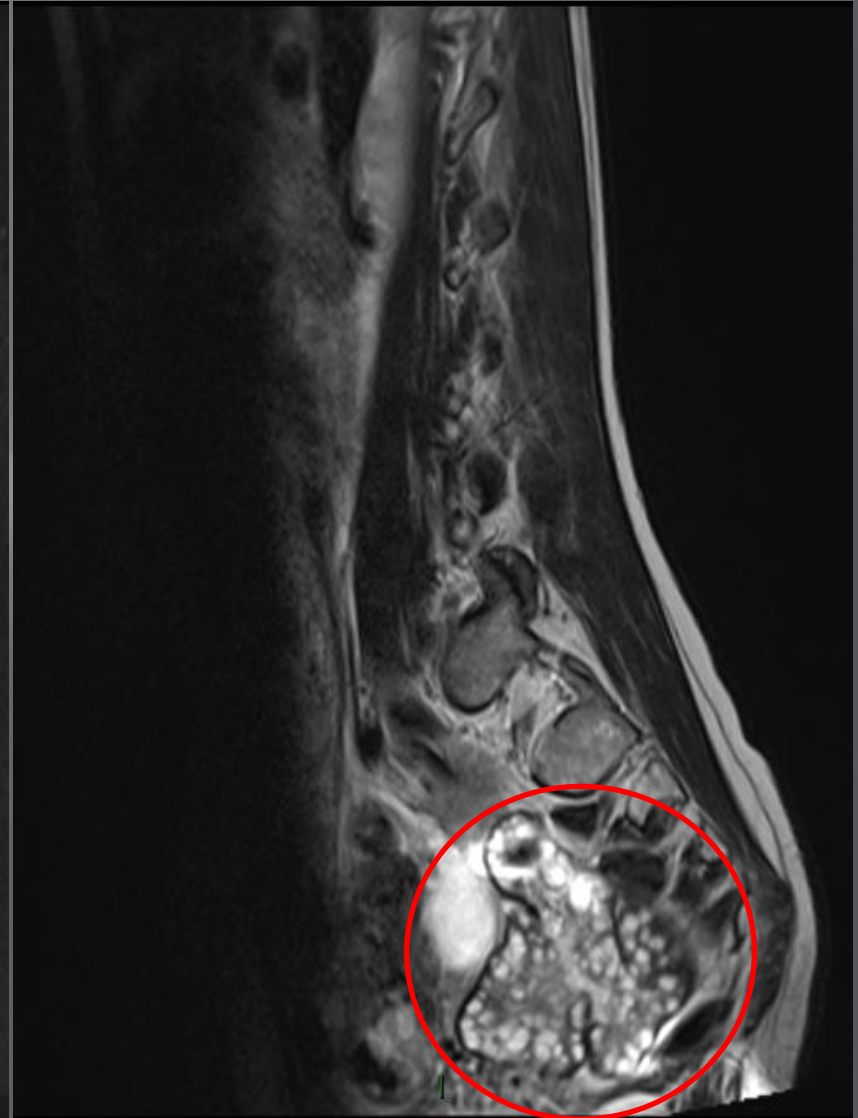Duplex ureters on left (with 1 dilated)



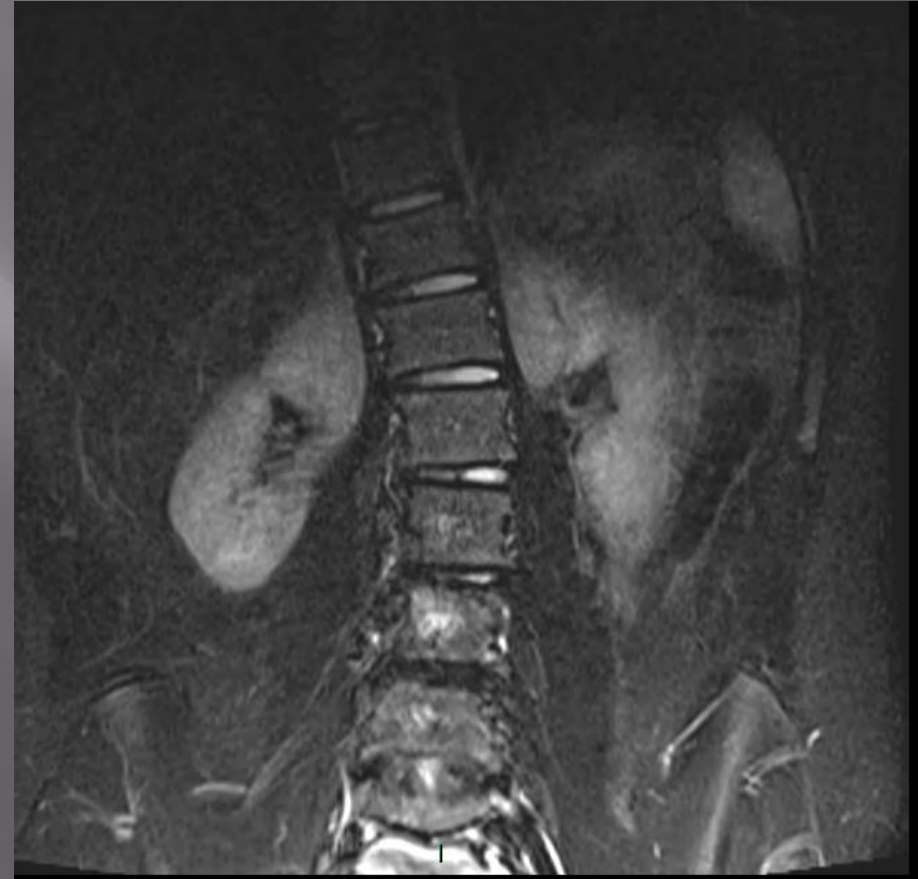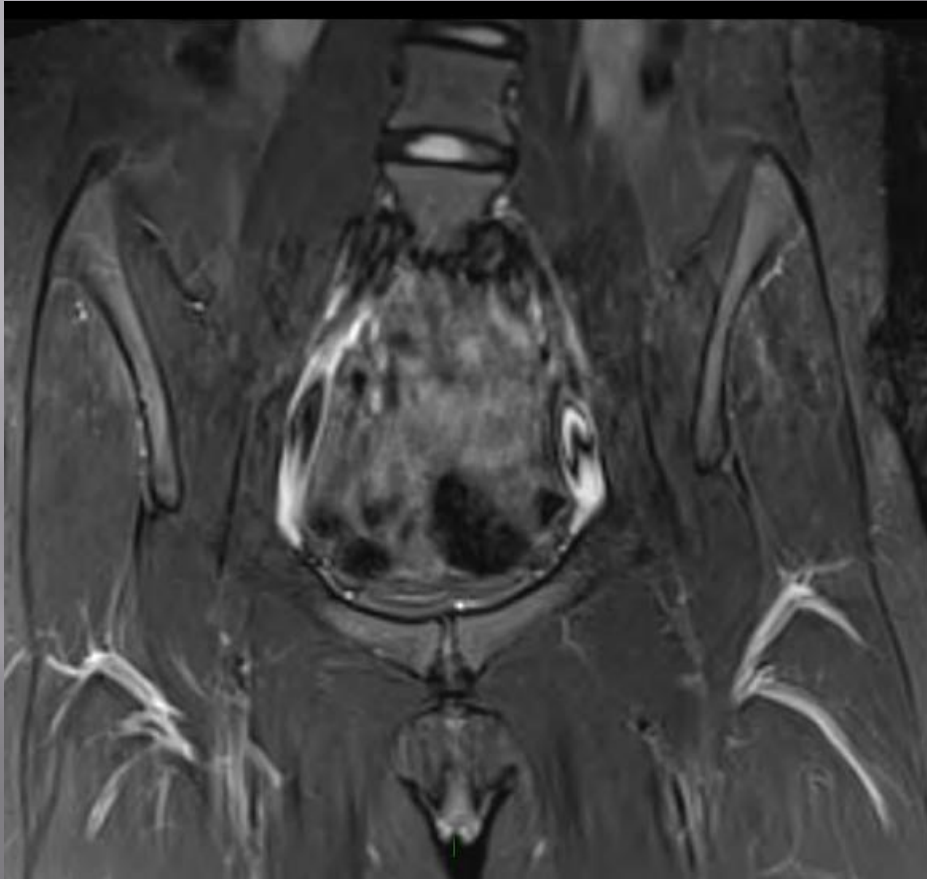
STIR COR



T₂ SAG

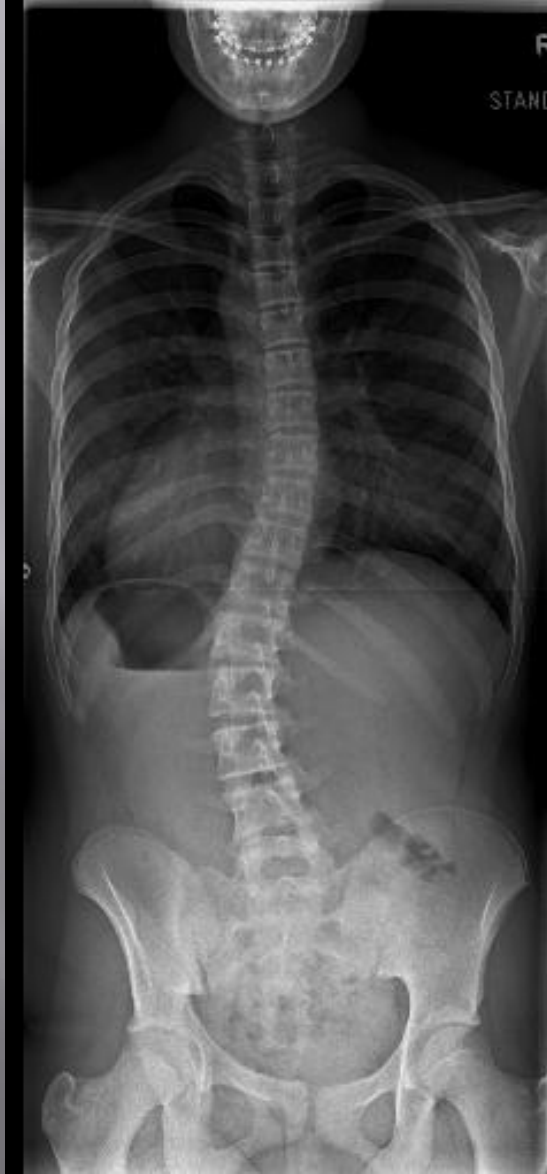

Decreased ROM in Lt hip. Normal X-ray. Referred for MRI Hips

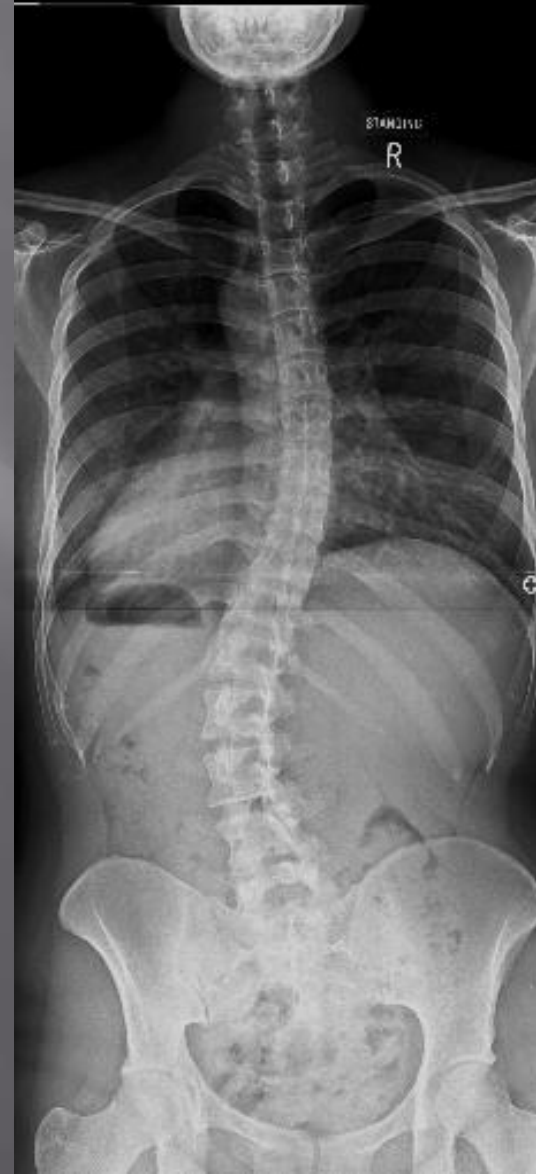

No surgical intervention and curve has changed very little since 2011

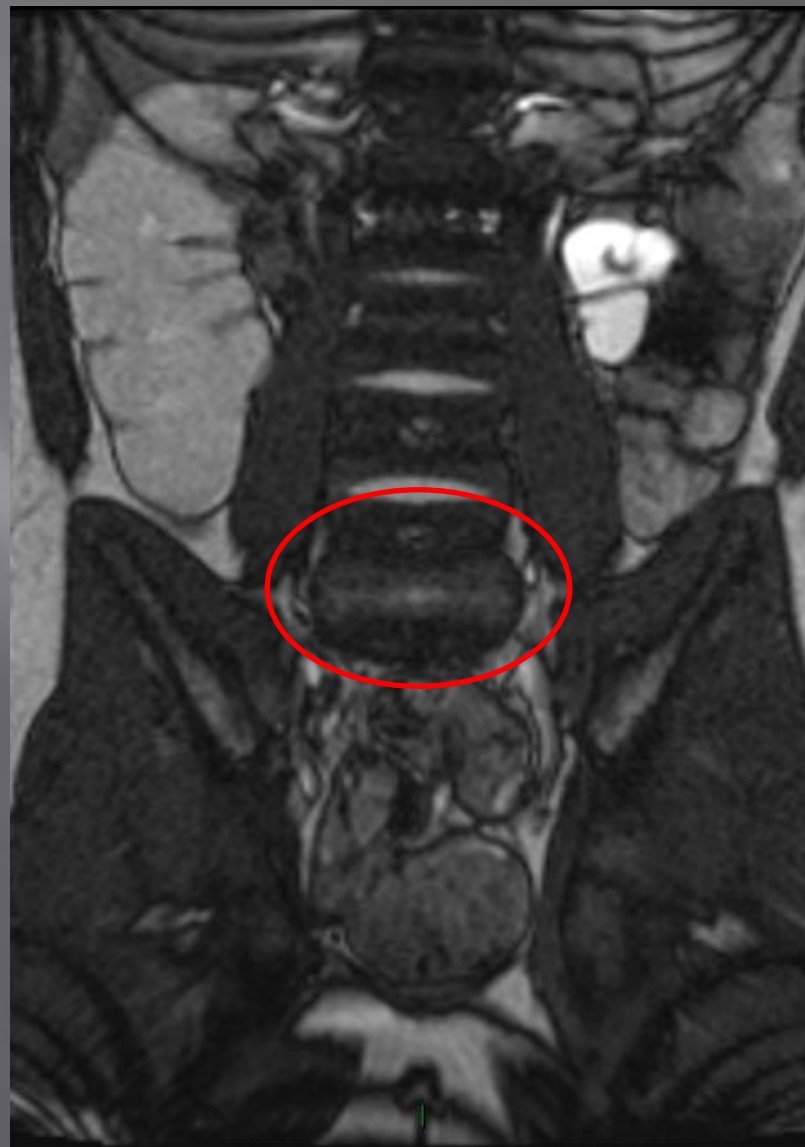
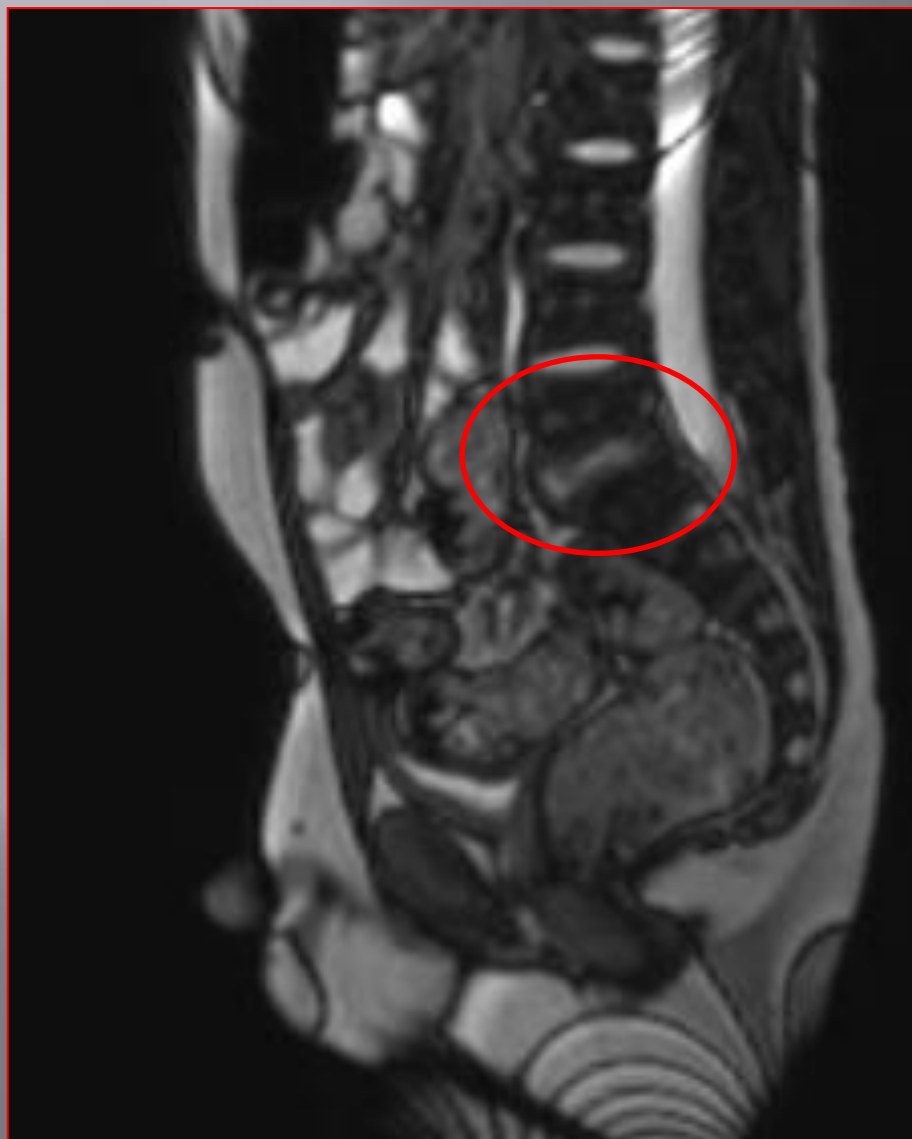2011

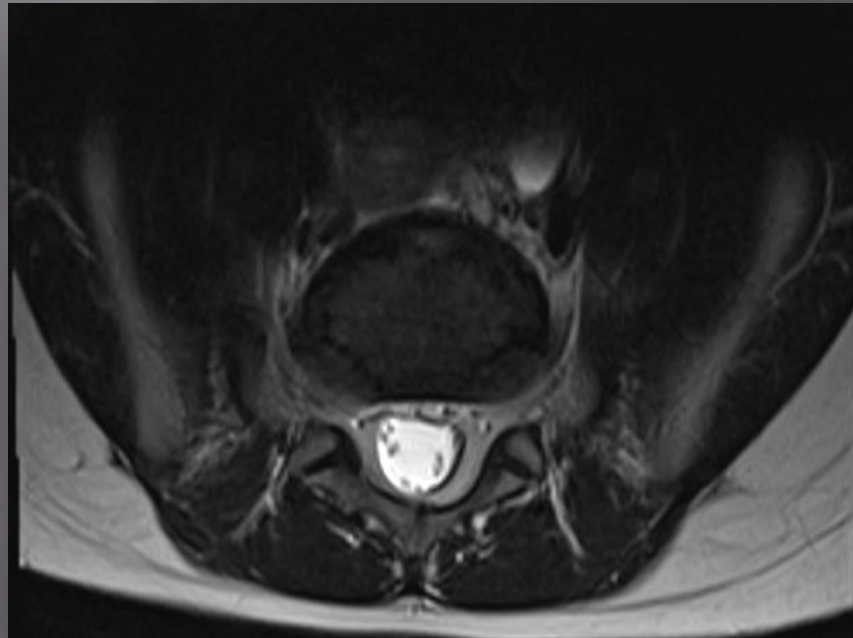
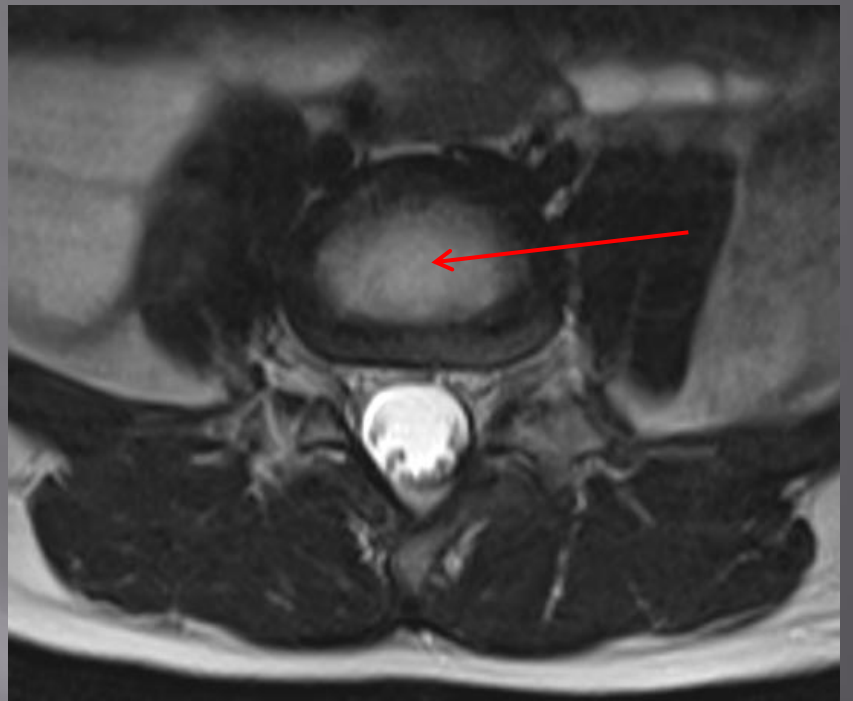
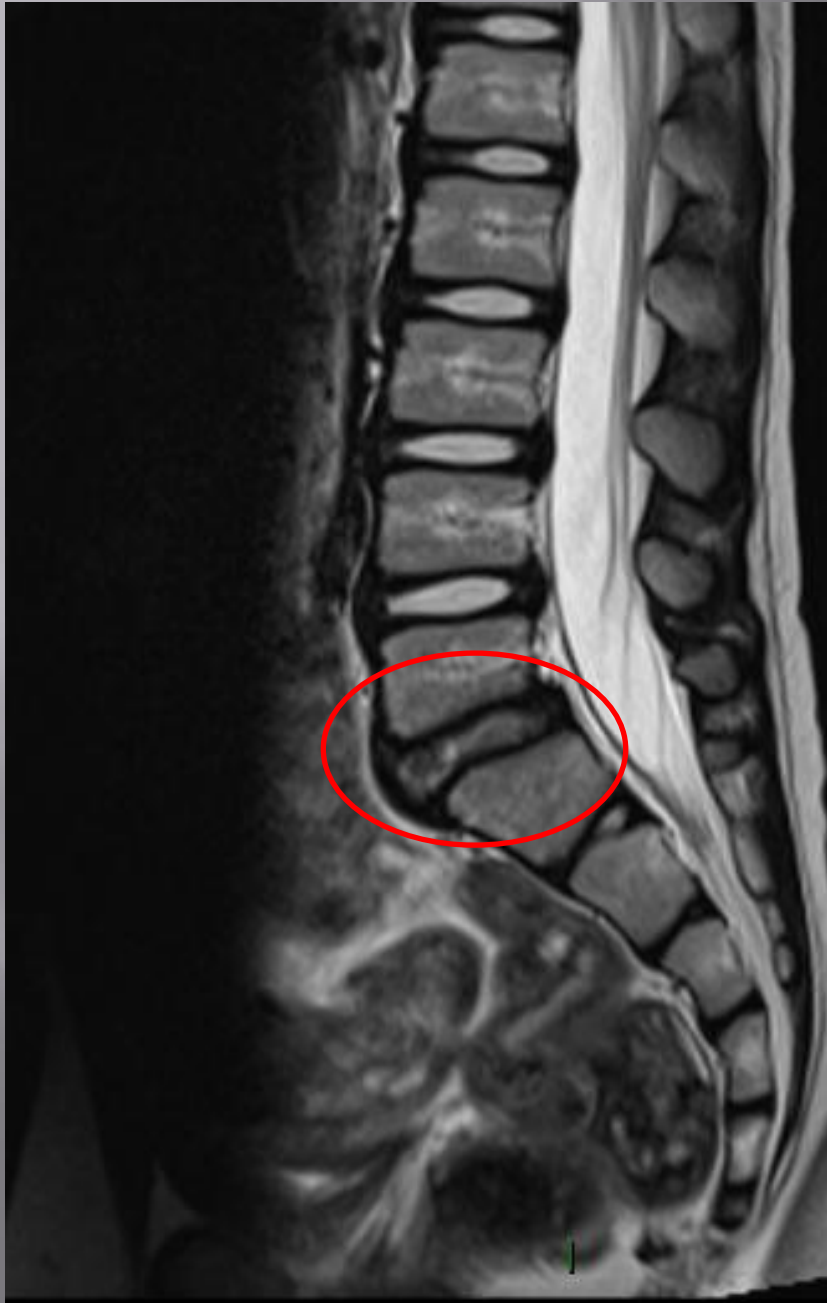

2019



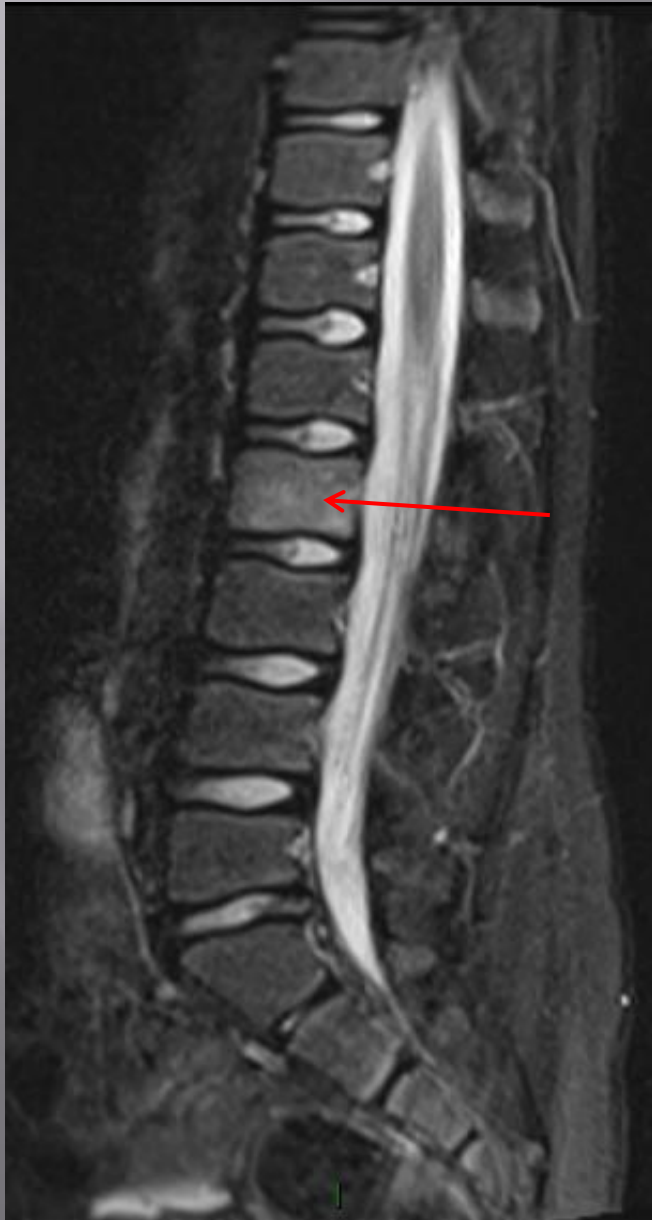MR SBFT for patient with non specific abdo pain.



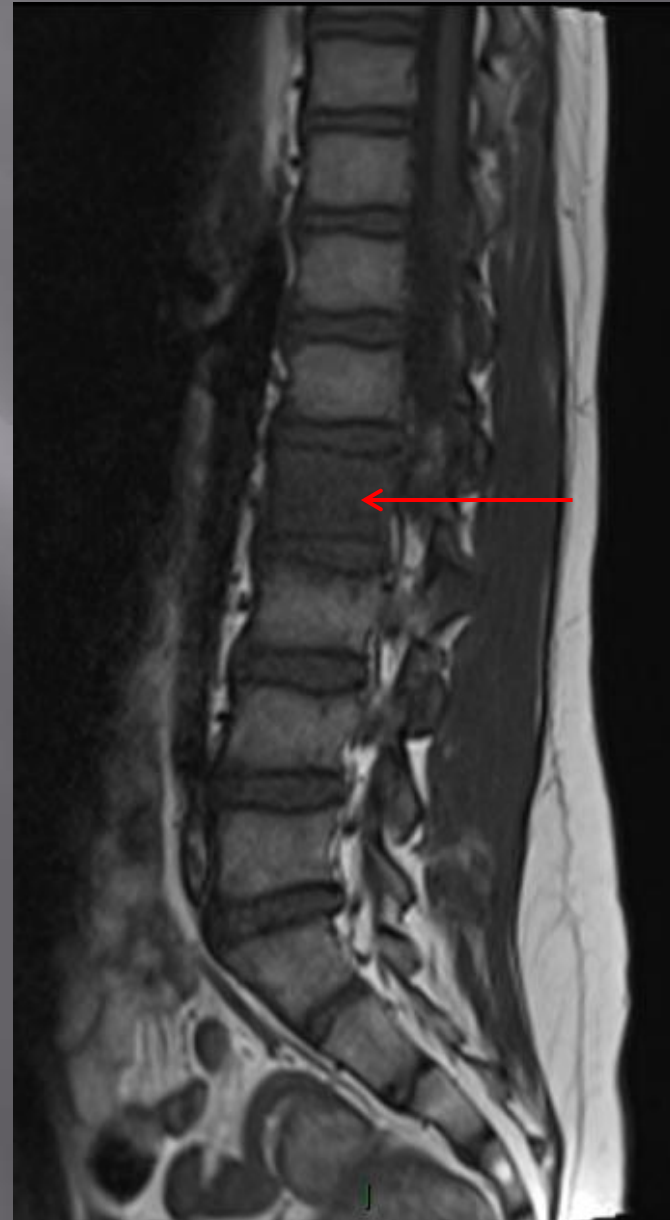

Fall from bike with Lt hip pain. Now evolving back pain

T₂ SAG



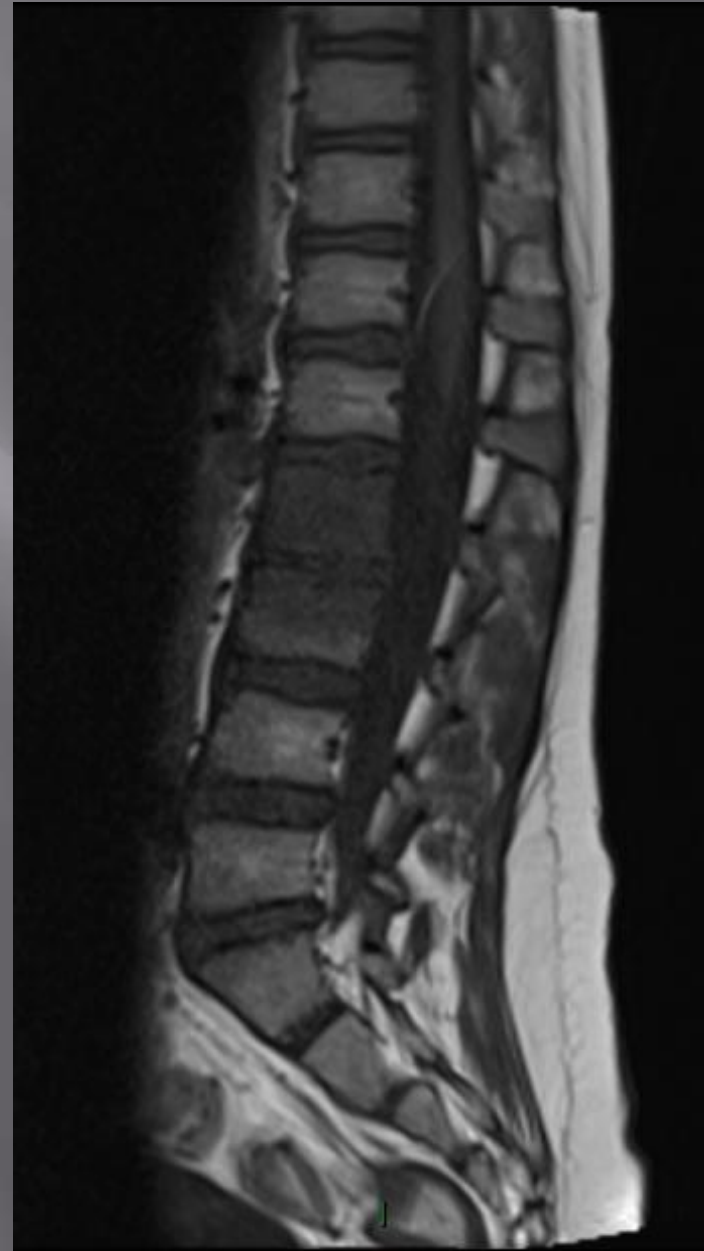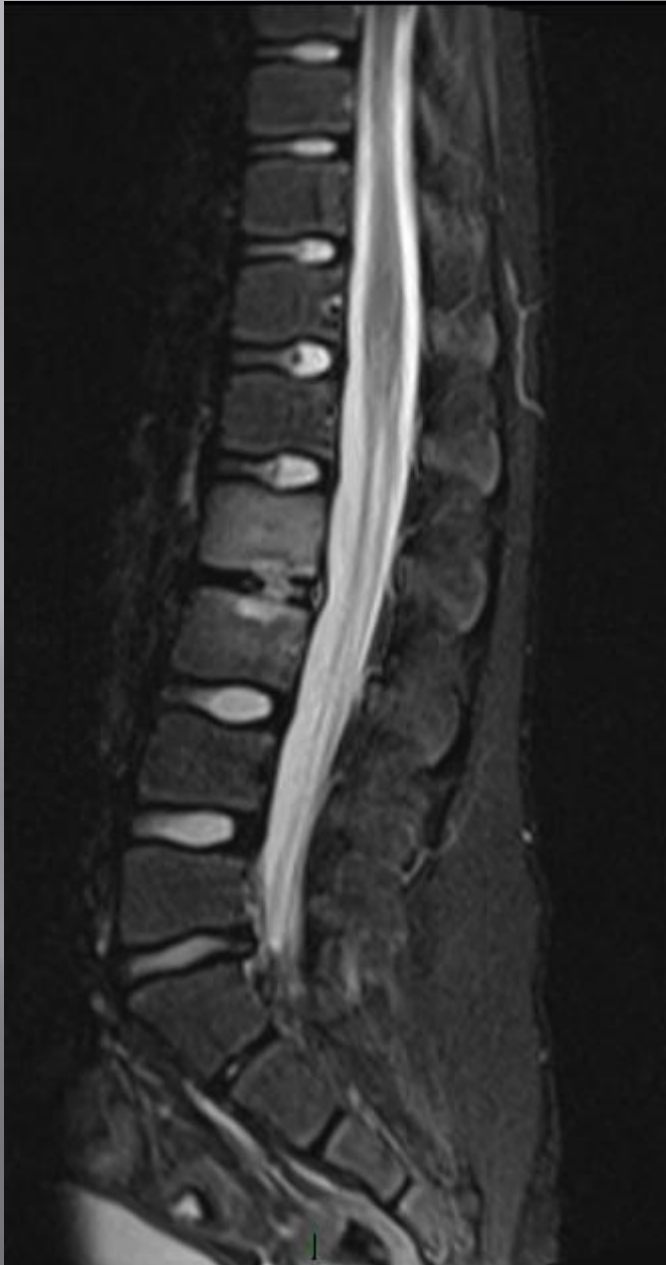T₁ SAG



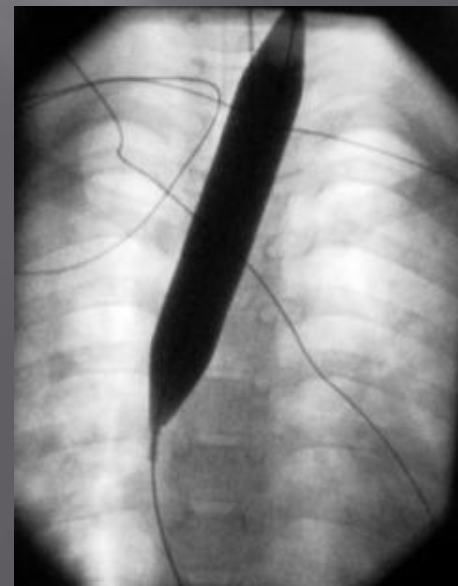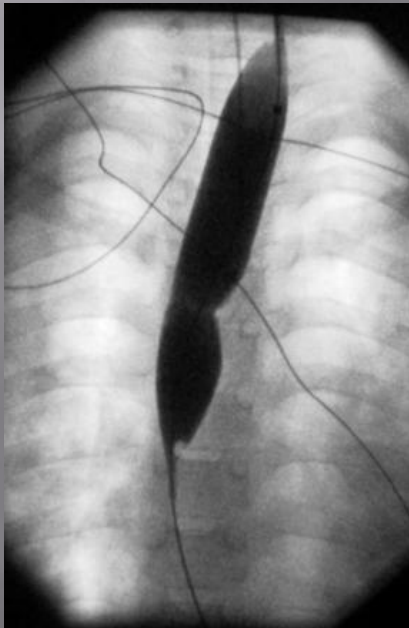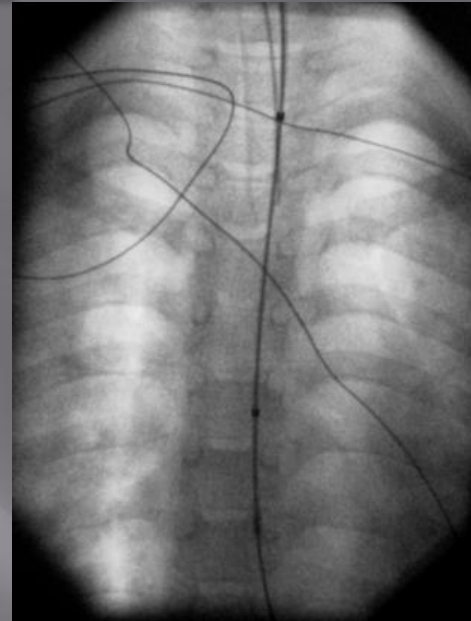
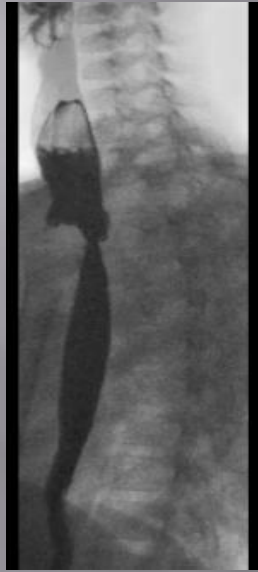Discitis and osteomyelitis

T₂ SAG

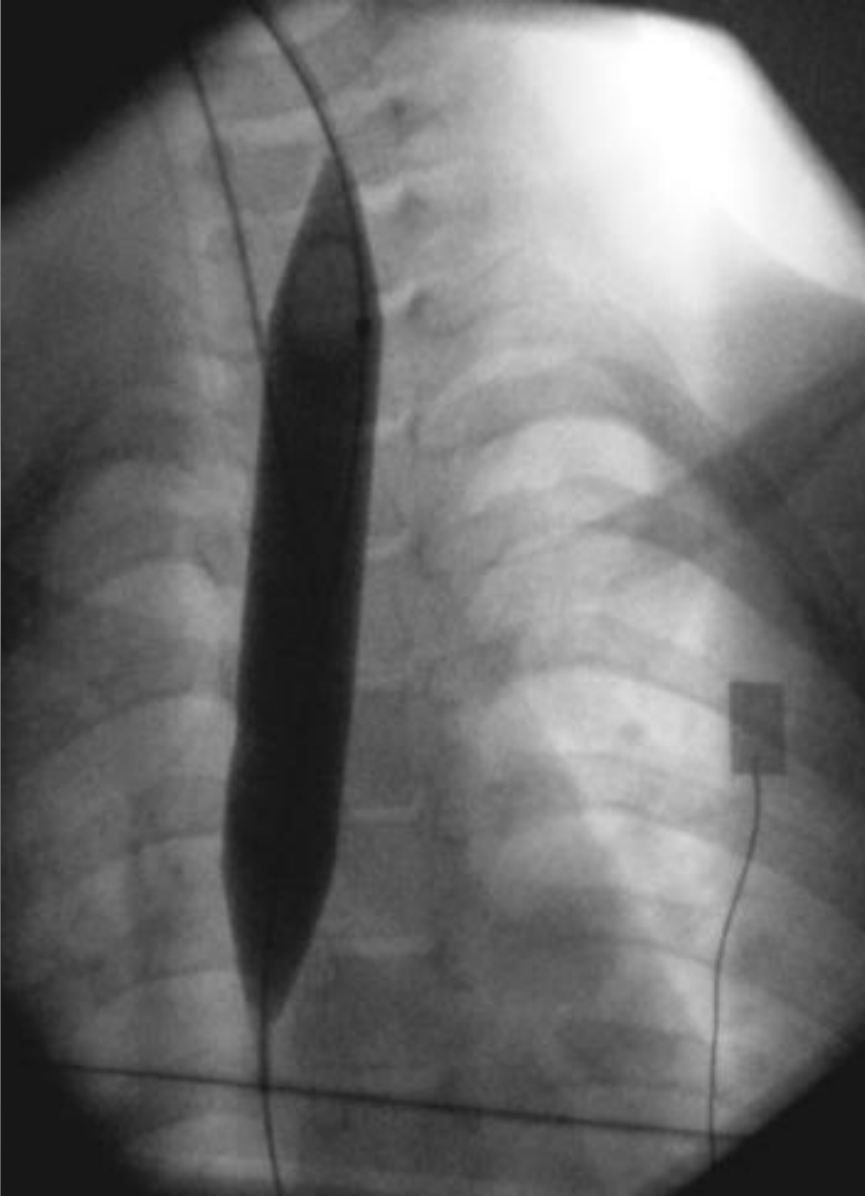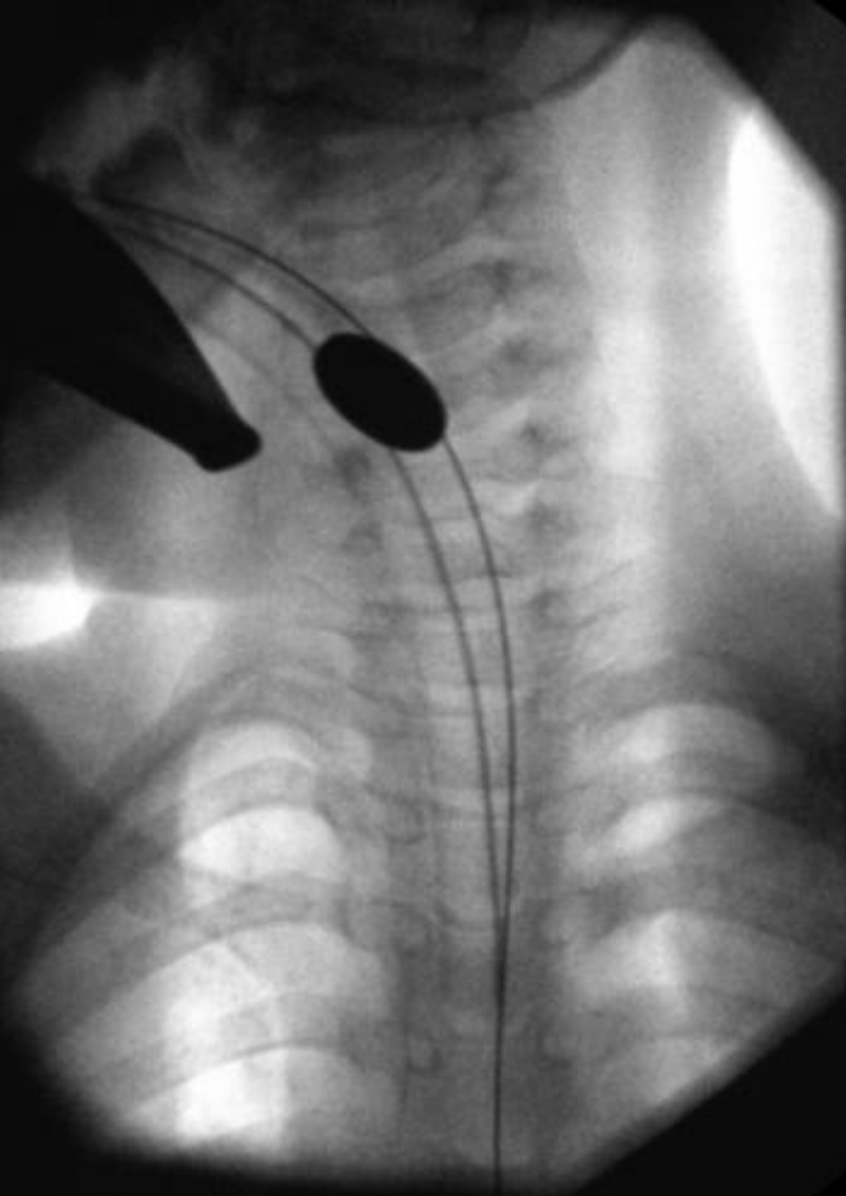
T₁ SAG



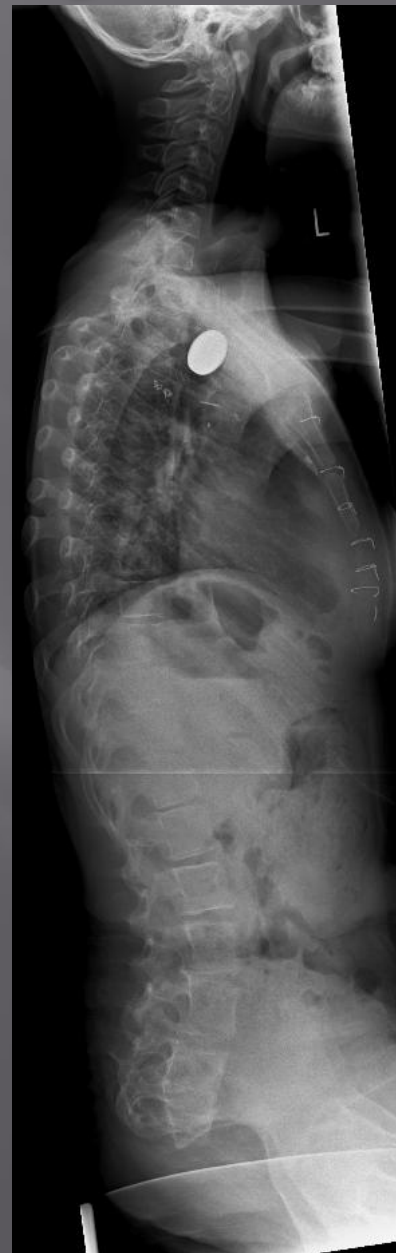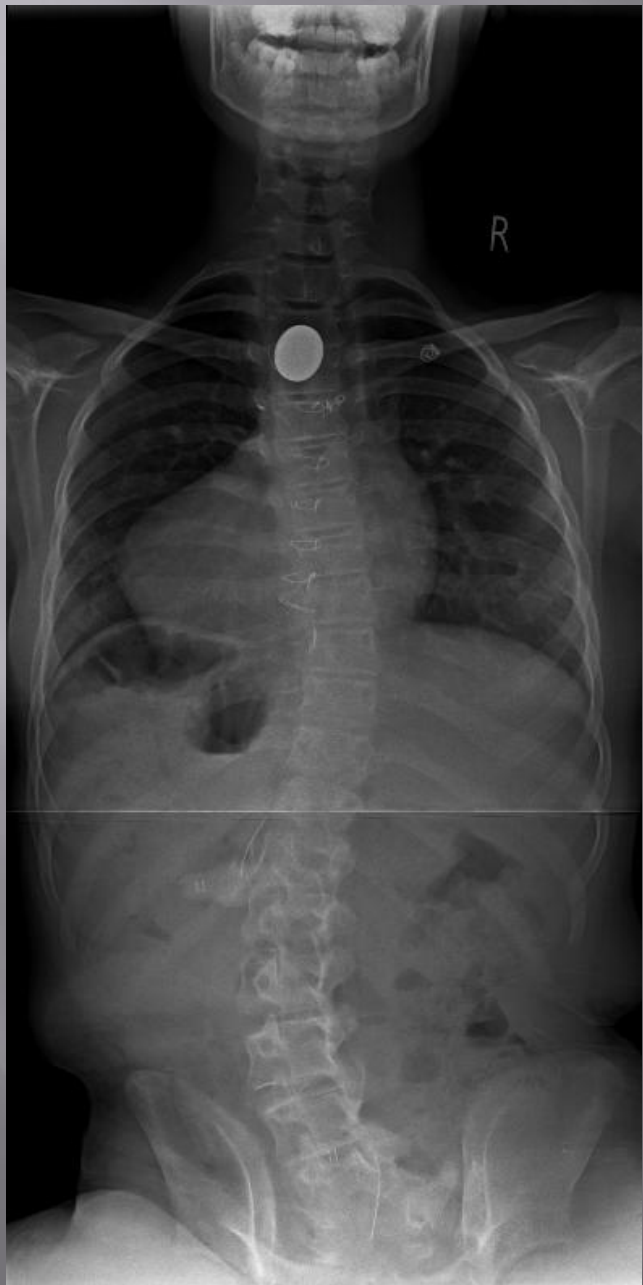Patient with recurrent stricture post oesophageal atresia repair requiring regular dilatations.

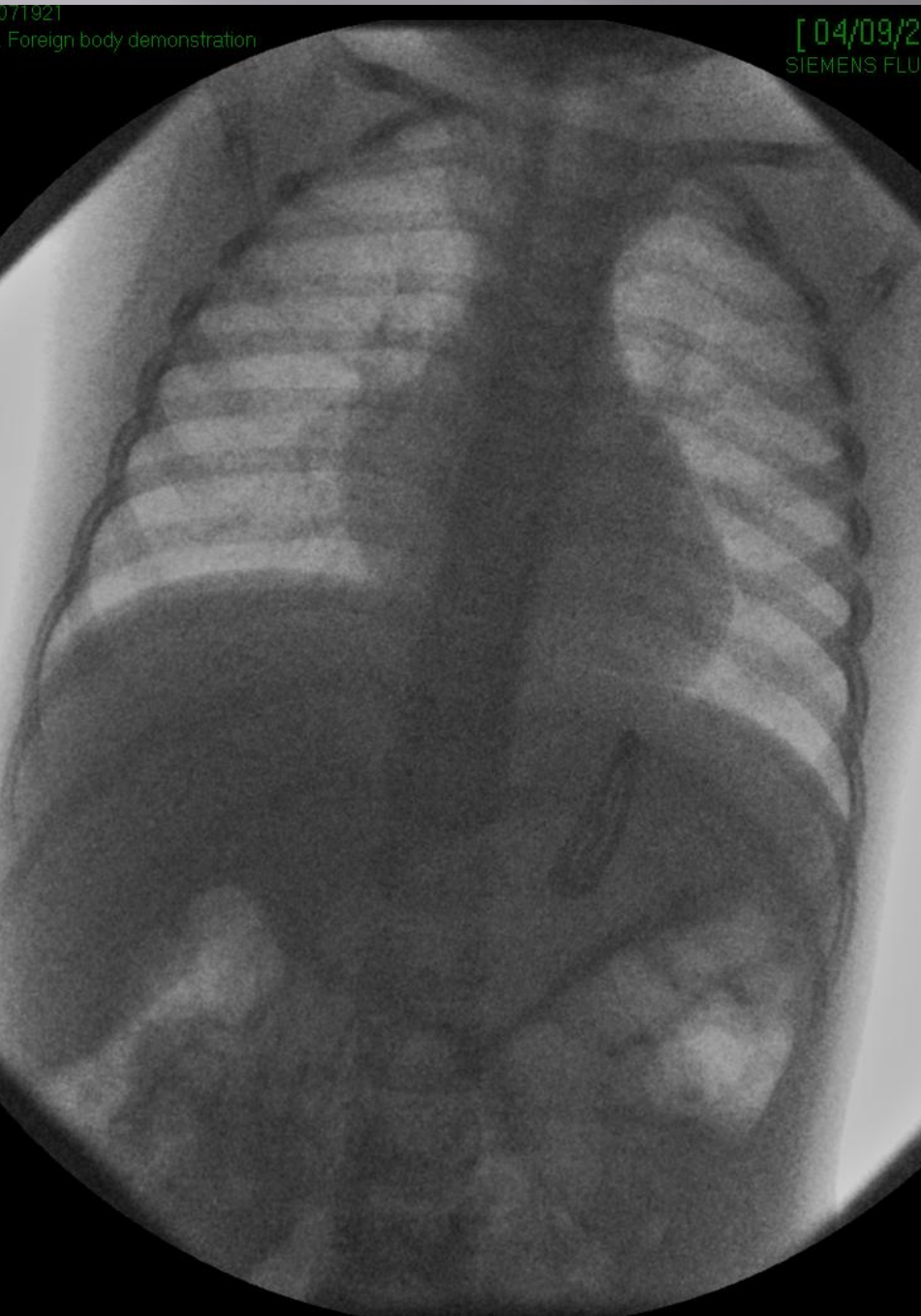

Unexpected finding of a £1 once anaesthetised!

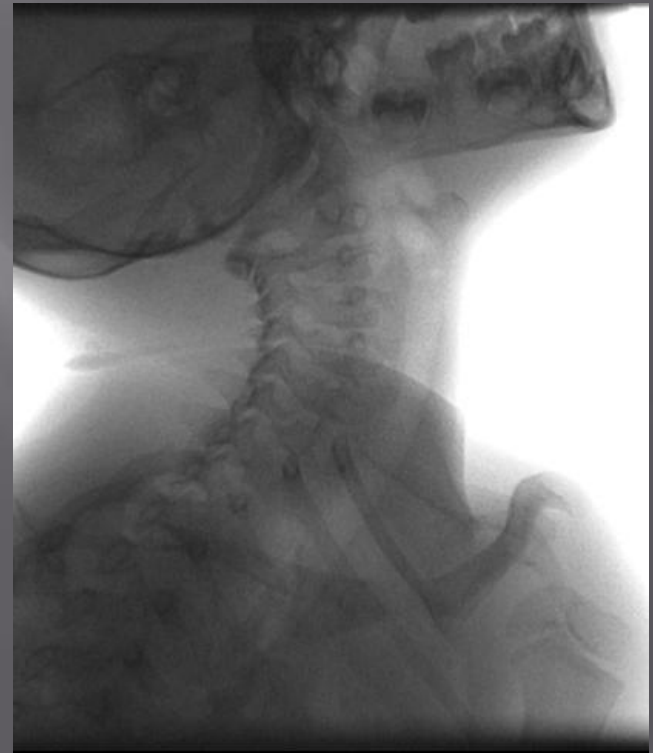

VACTERL patient with evolving scoliosis

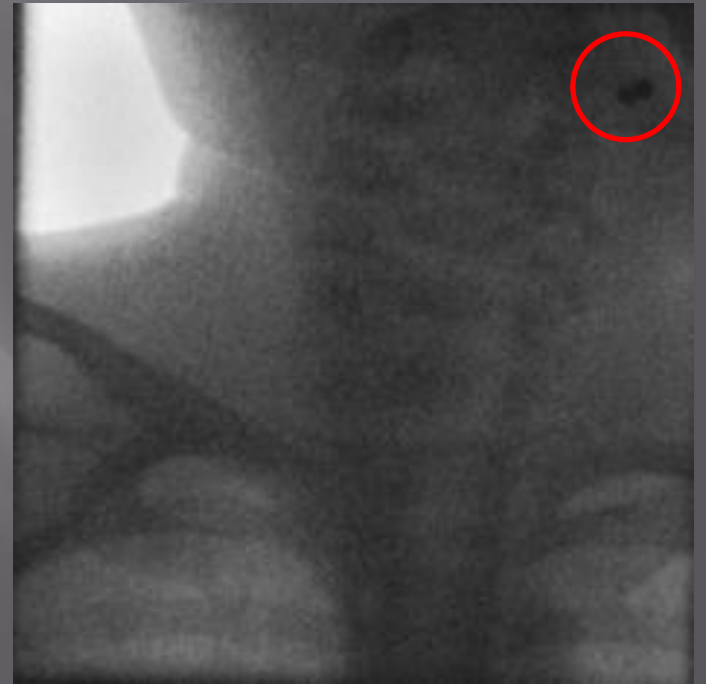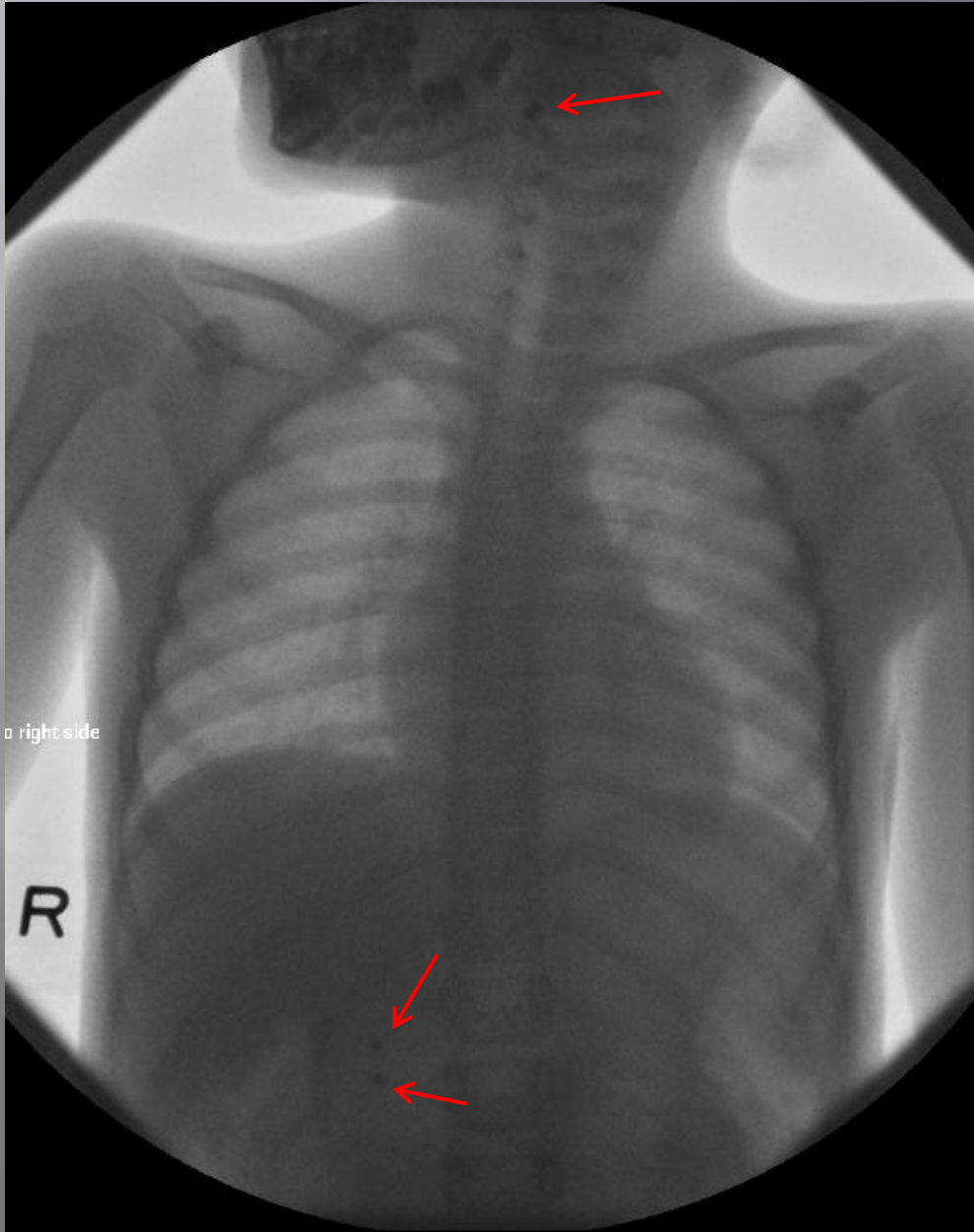




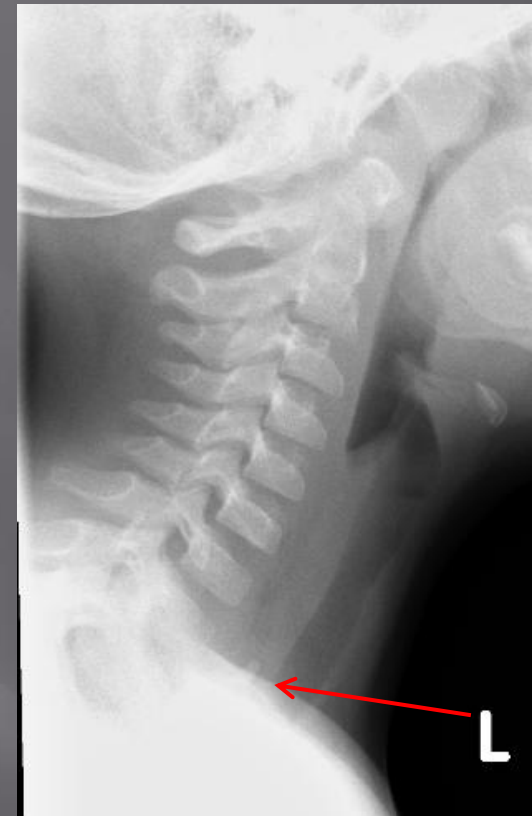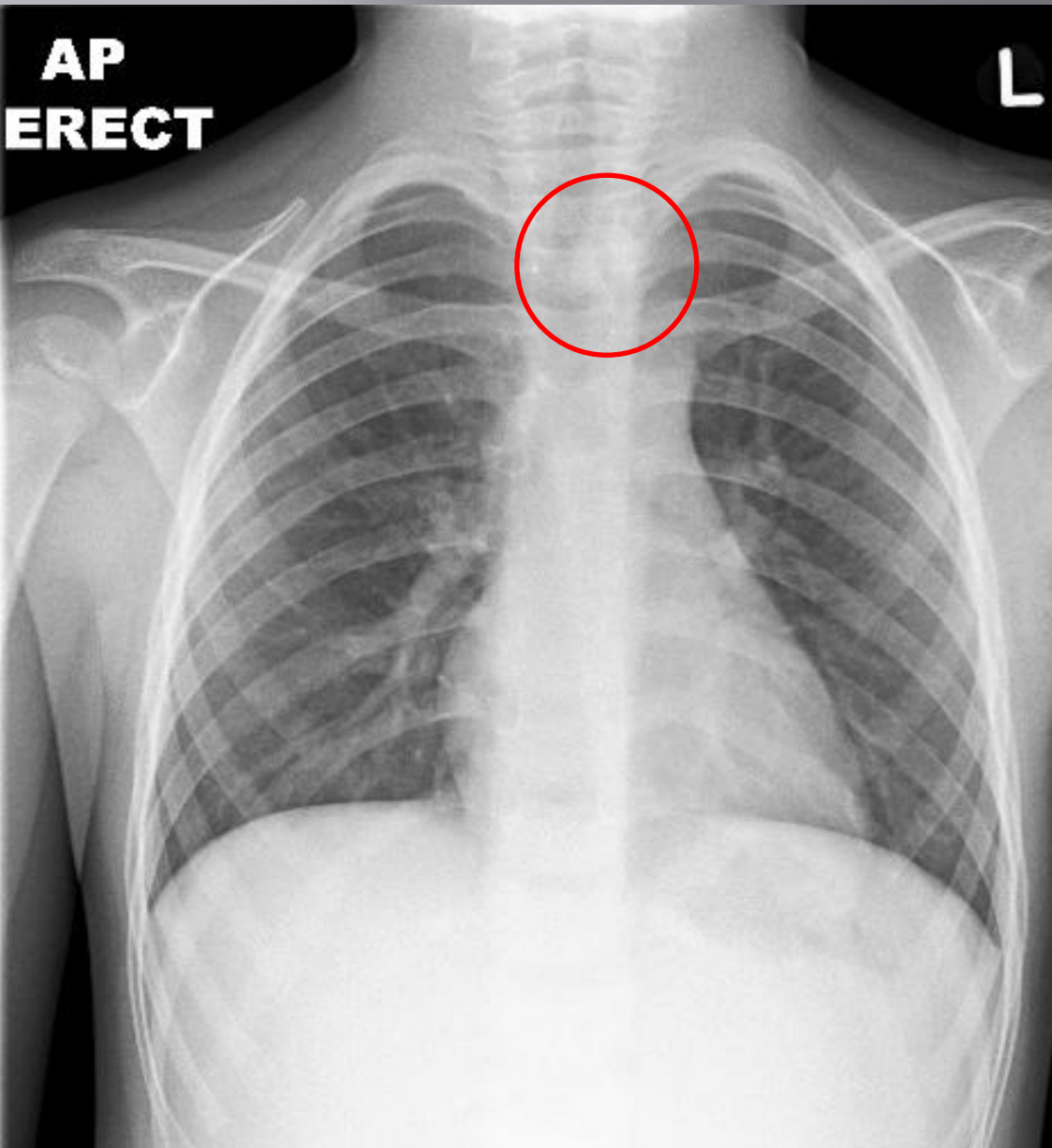
Patient swallowed a
'Hello Kitty' hair
clasp



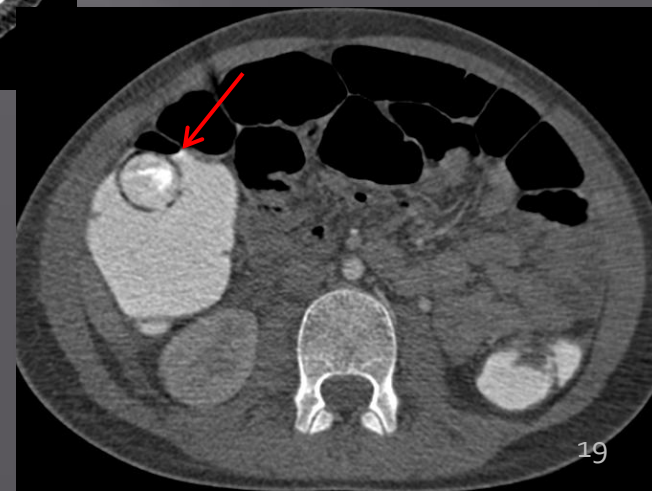
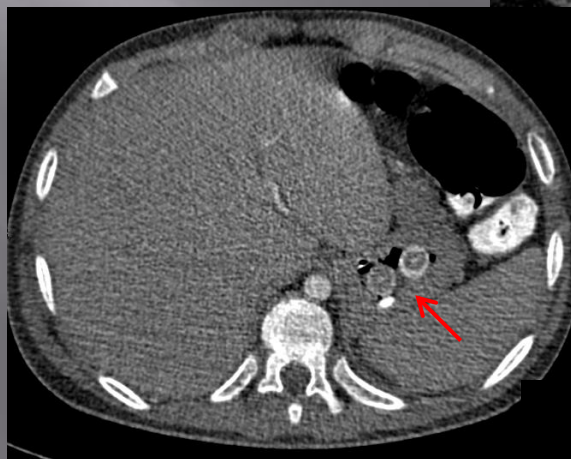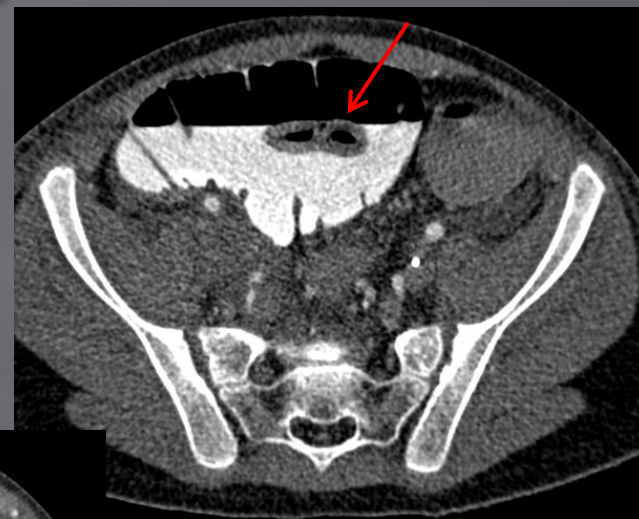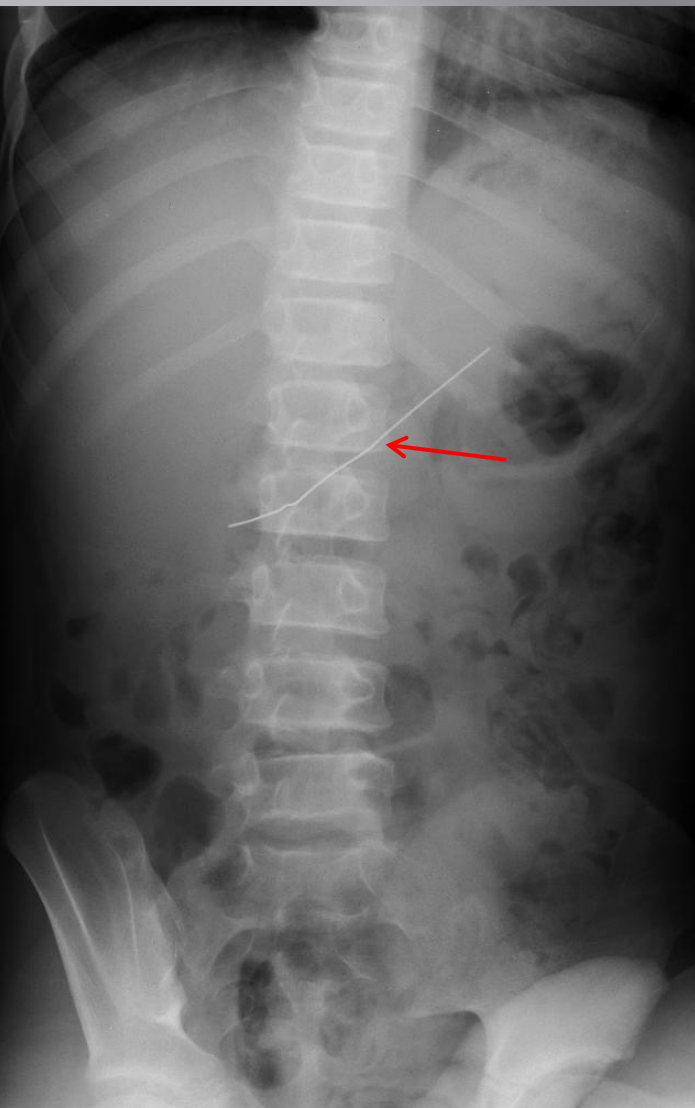
Swallowed 4 magnetic ball bearings



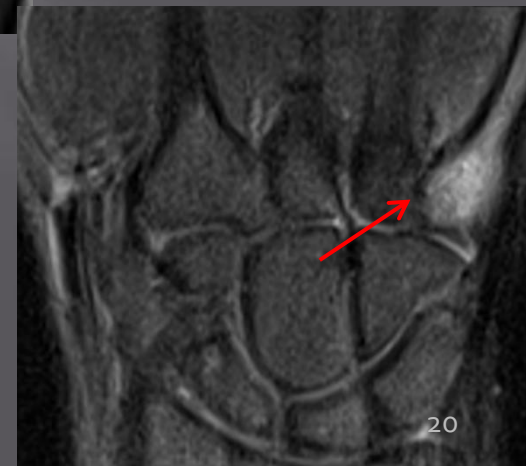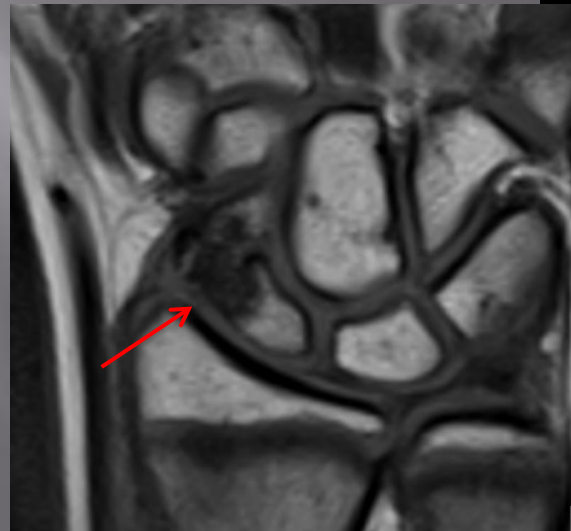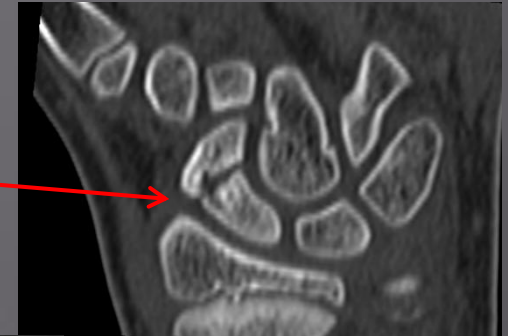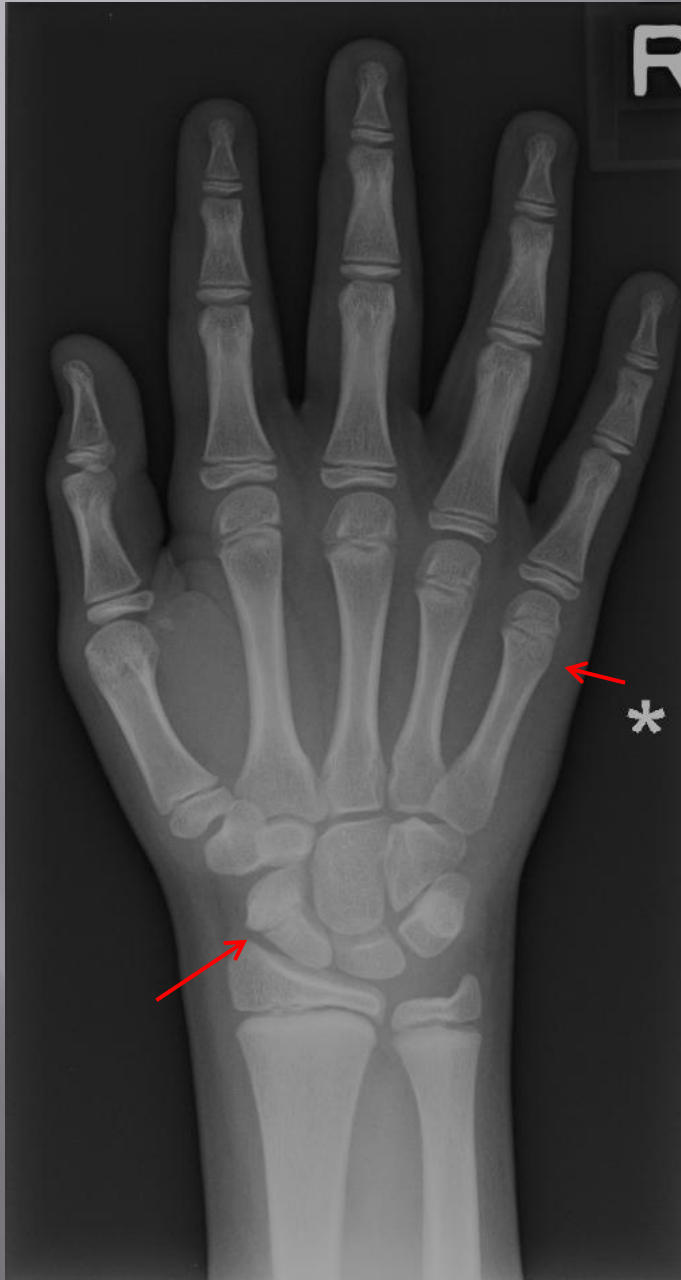Swallowed plastic toy 3/7 ago. Drooling, vomiting, coughing since.



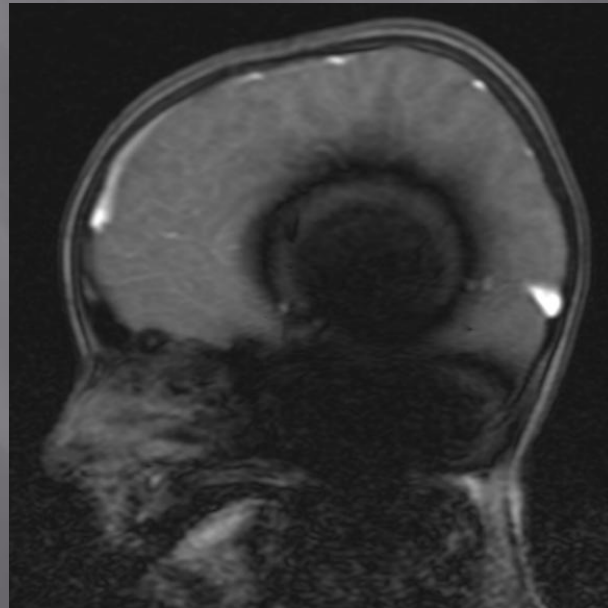
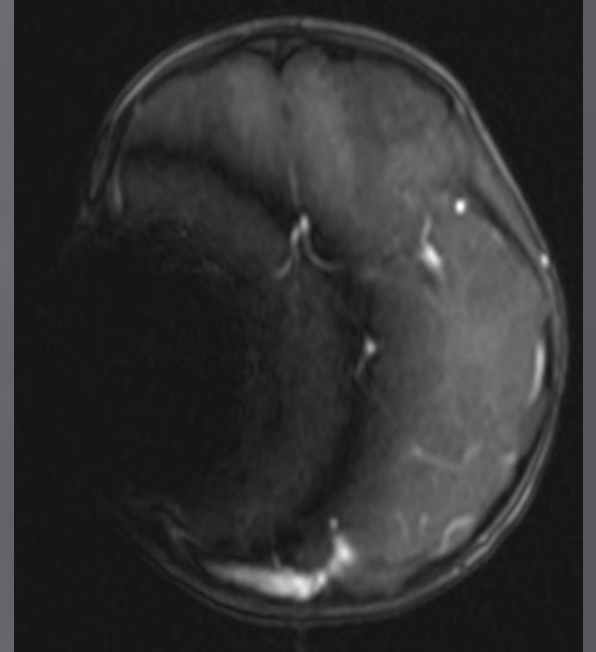
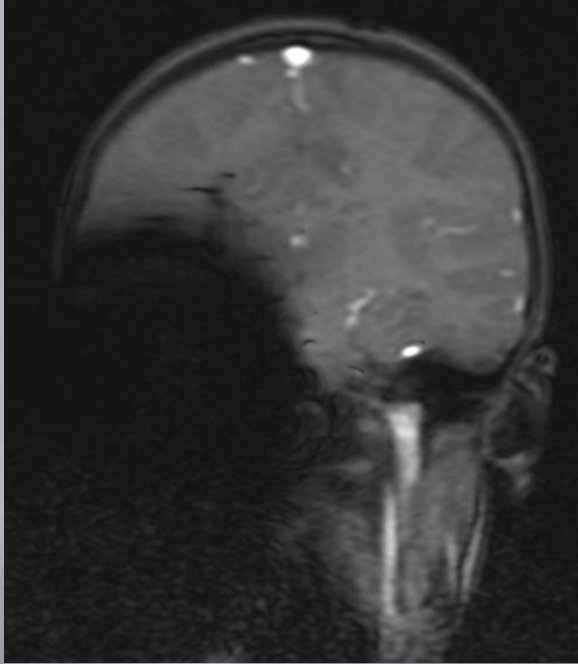
Patient with learning difficulties and autism...and an eating disorder!



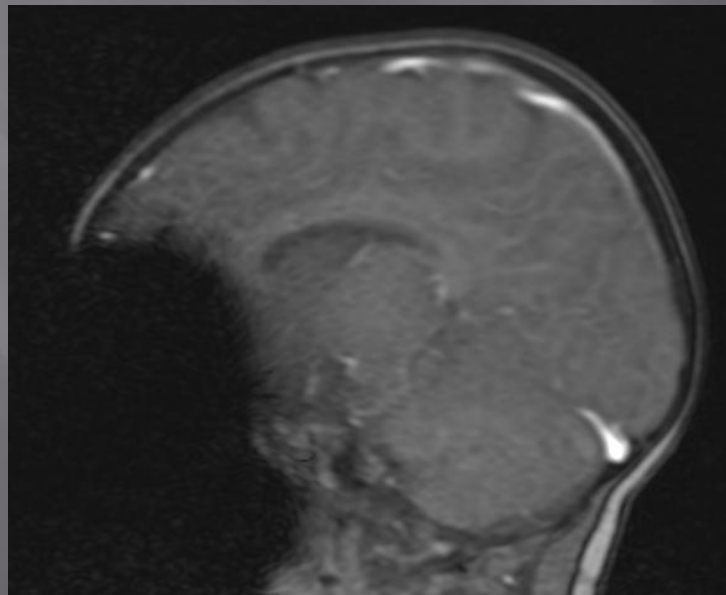
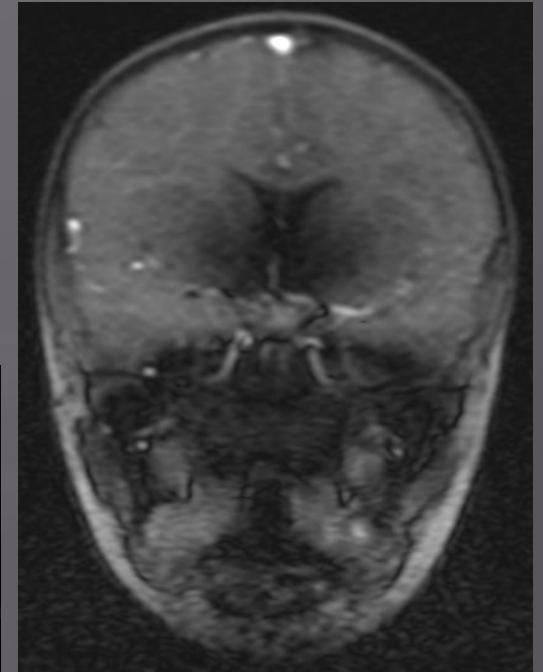
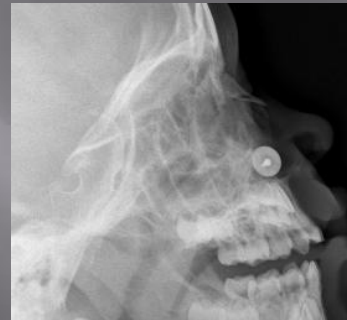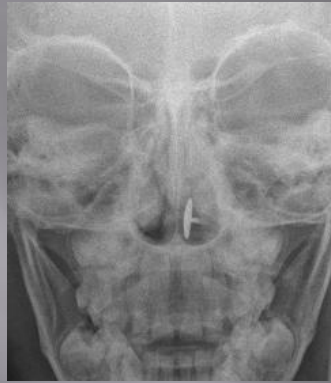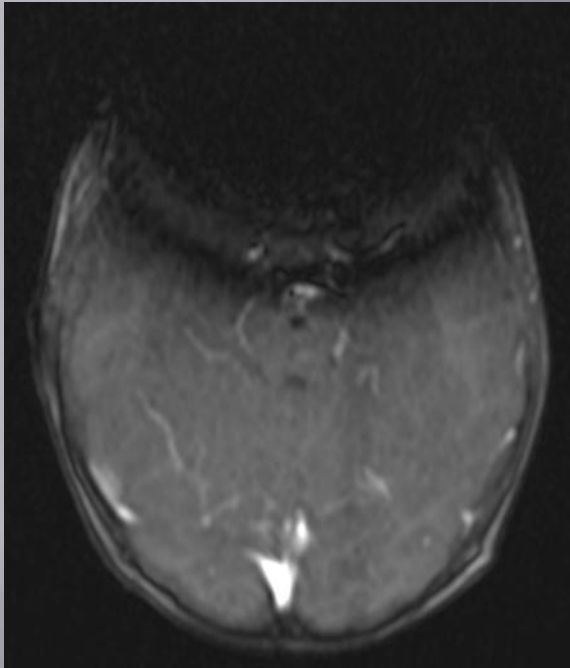
10 year old who punched a wall



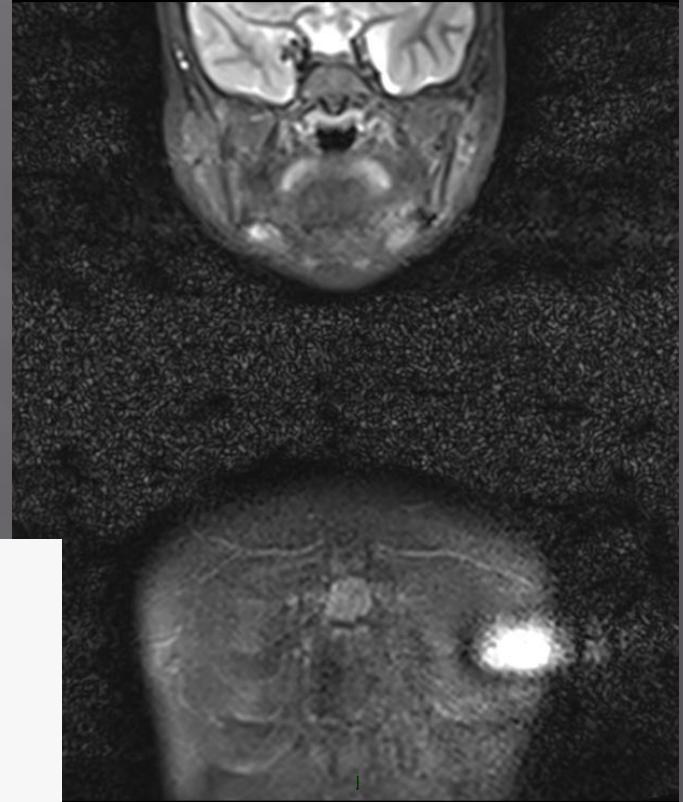
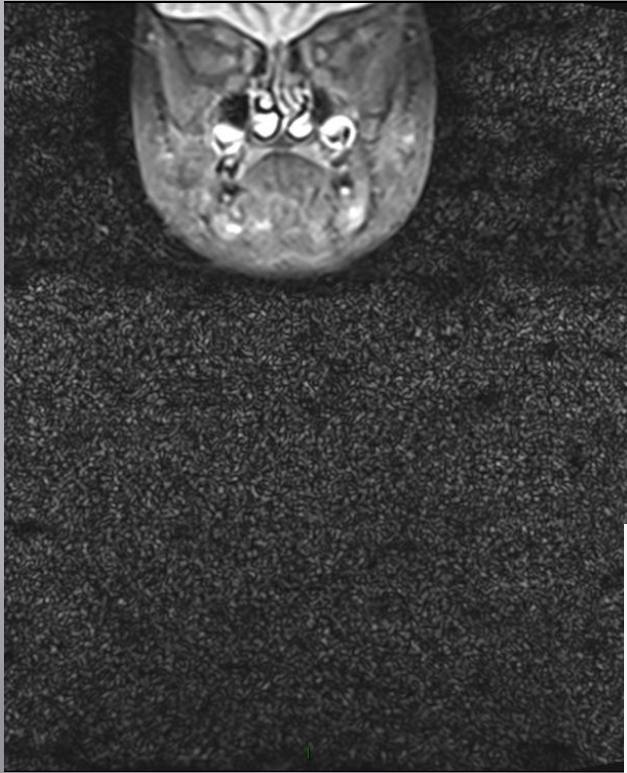Papilloedema and headaches



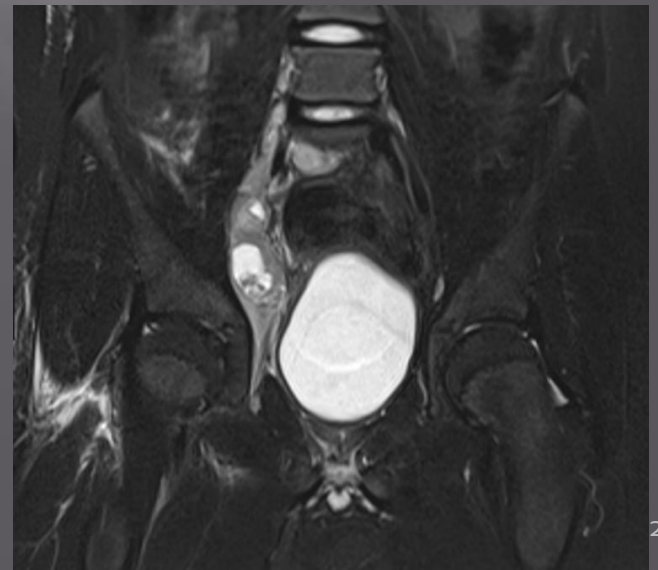
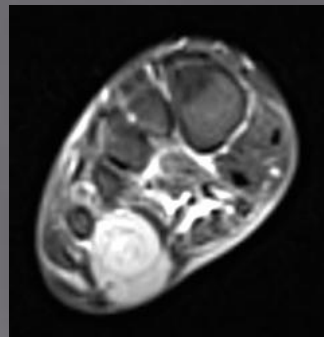
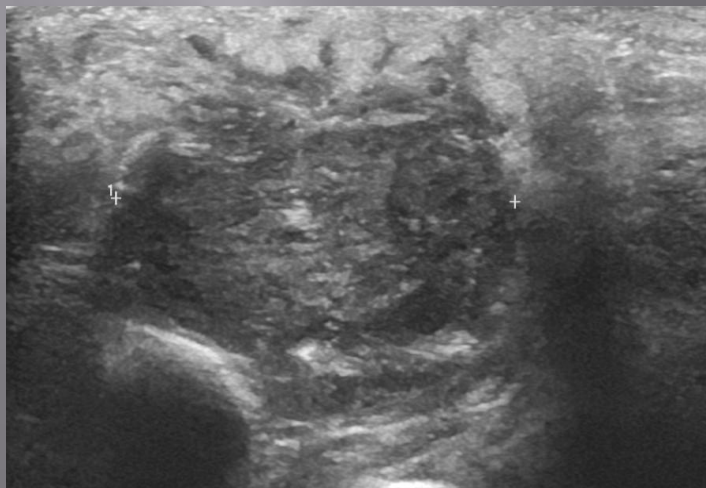
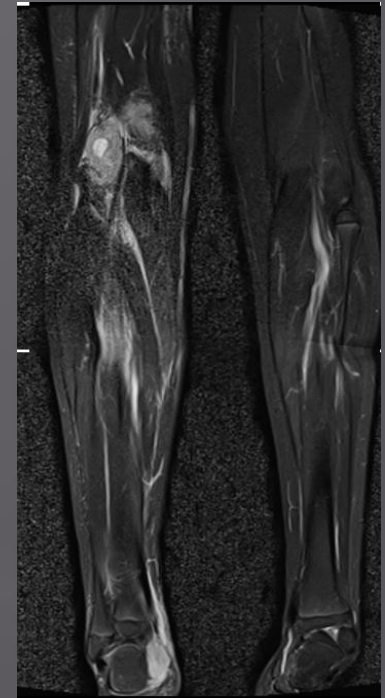
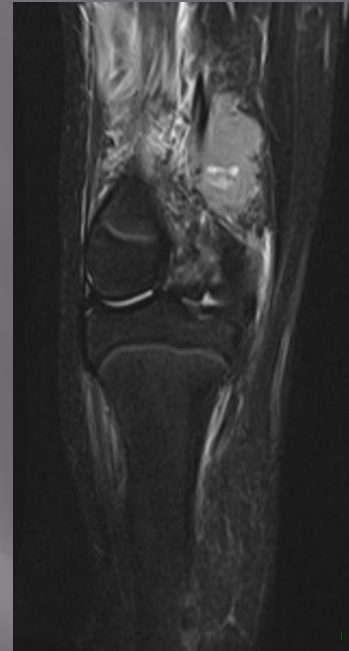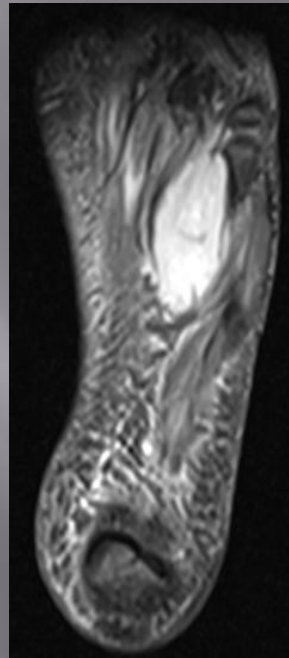
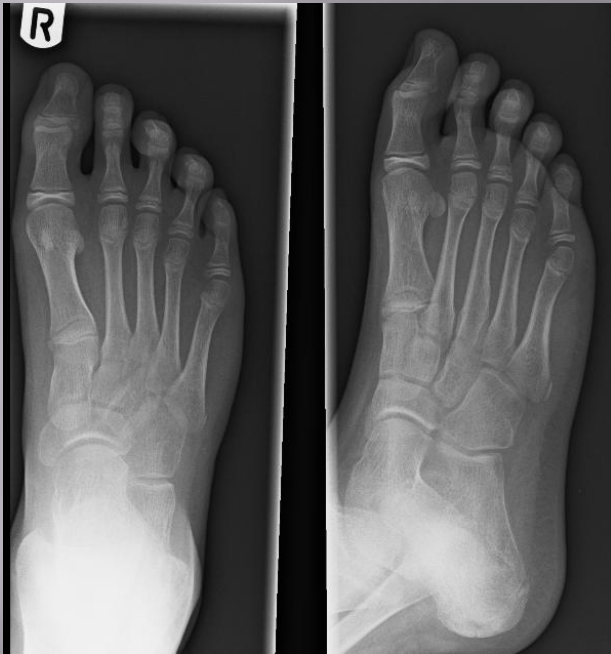MRI showing signal drop off in localisers



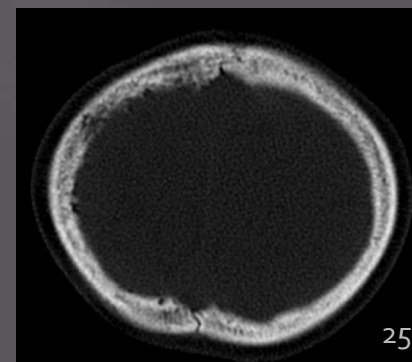
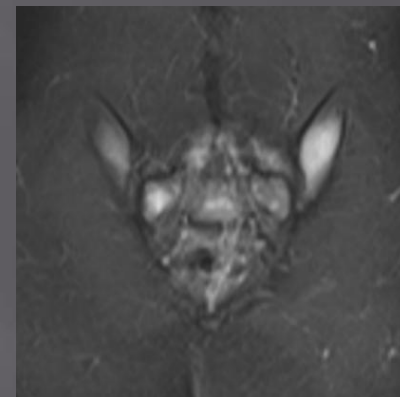
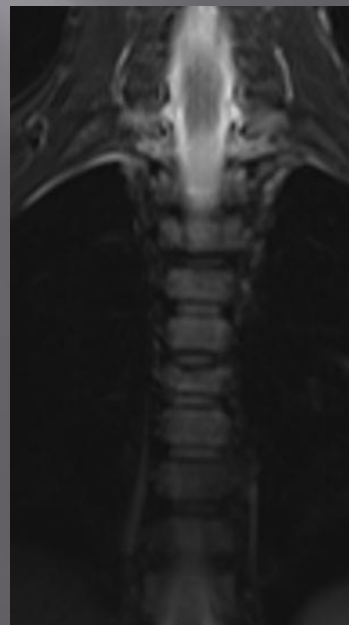
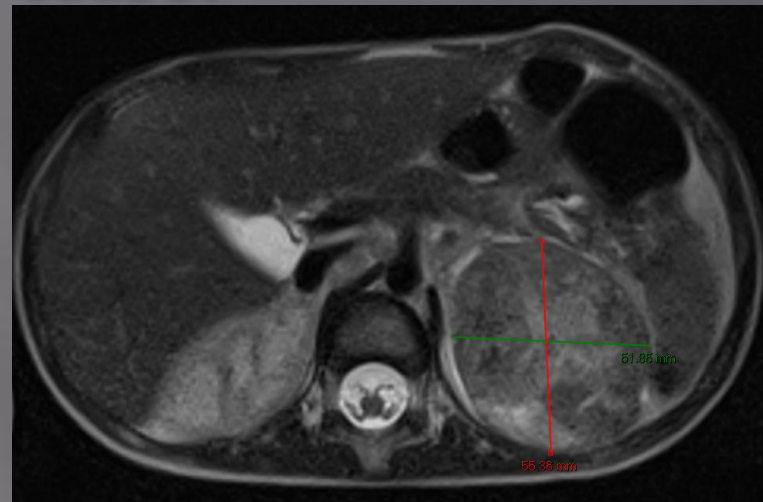
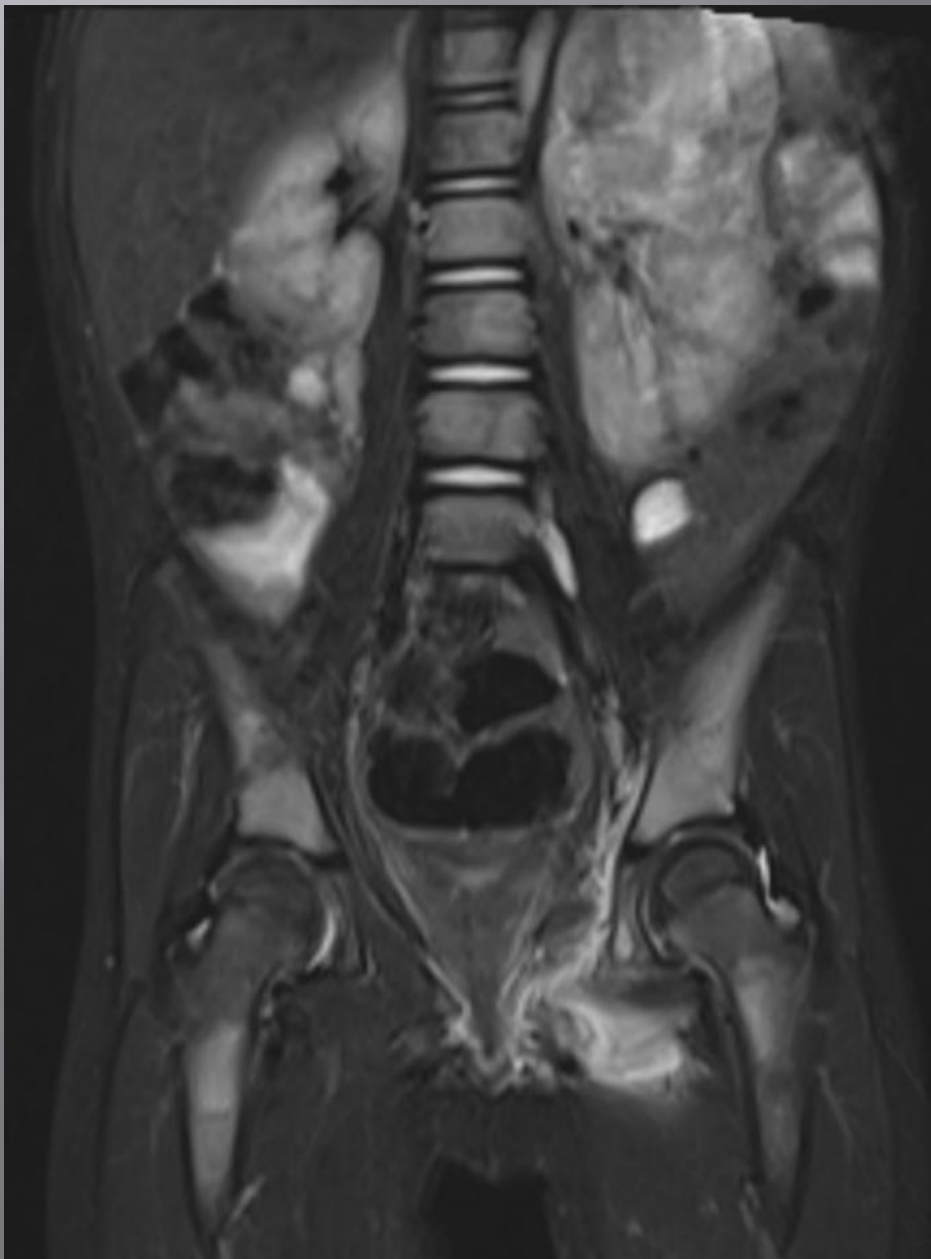
Beware the sparkly tee shirt!



Rapid increase swelling to foot ? FB

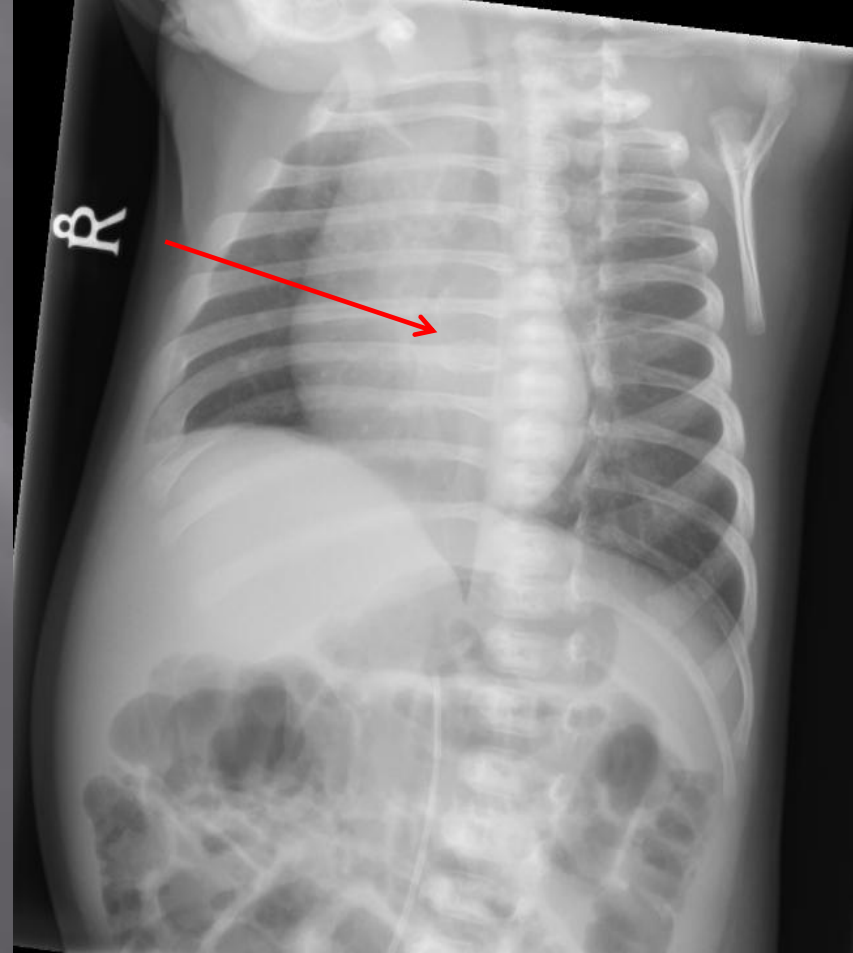
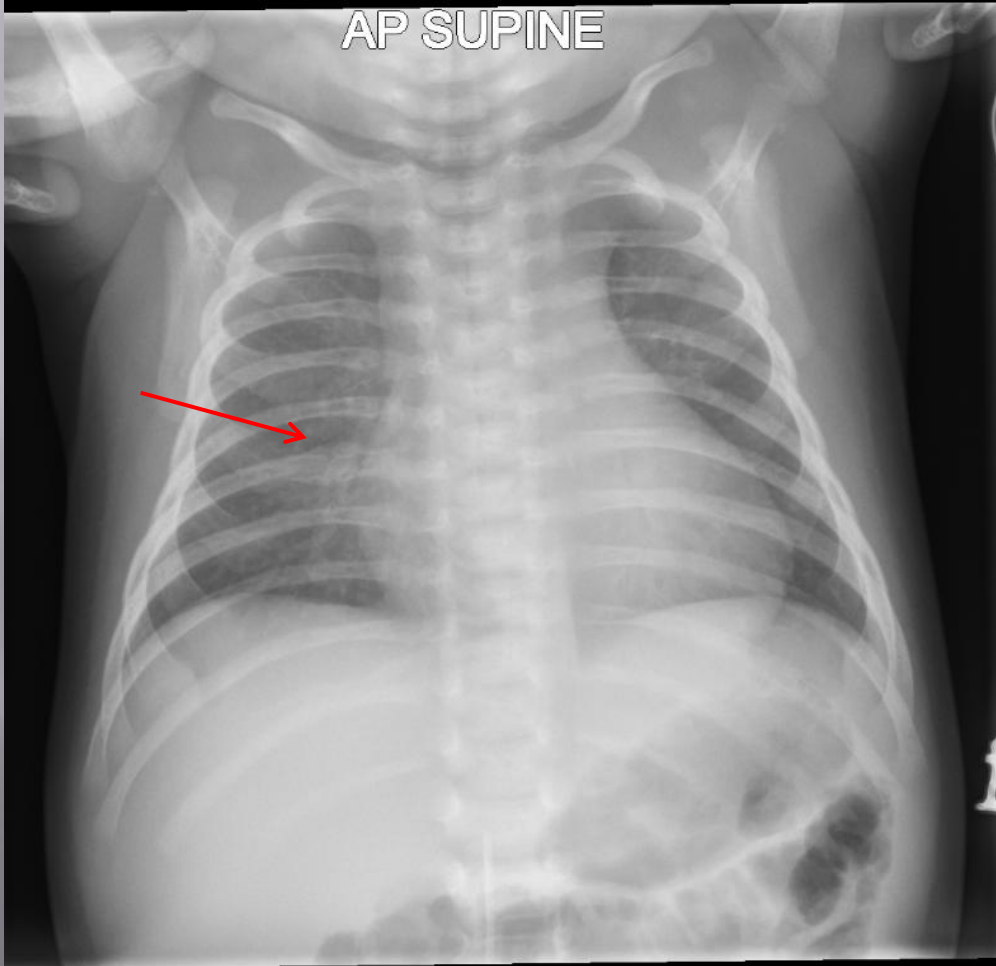


Lt hip pain, headaches, raised inflammatory markers. ? Cause.



5 week old in Resus with ? sepsis

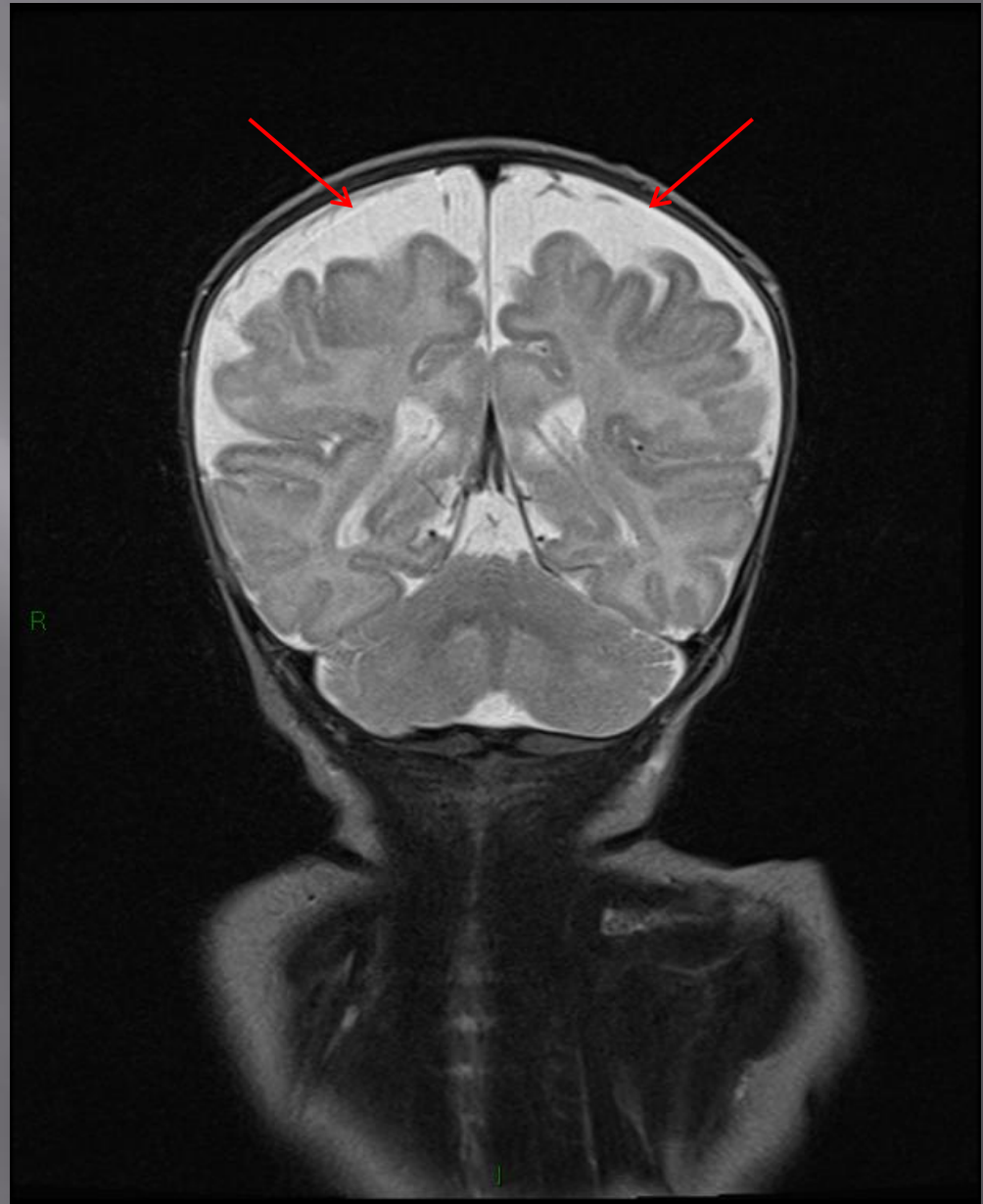
AP SUPINE



MRI (as part of NAI survey) shows enlarged extra-axial spaces.

X-rays showed abnormal bone texture.

? Underlying metabolic condition



Any questions????

