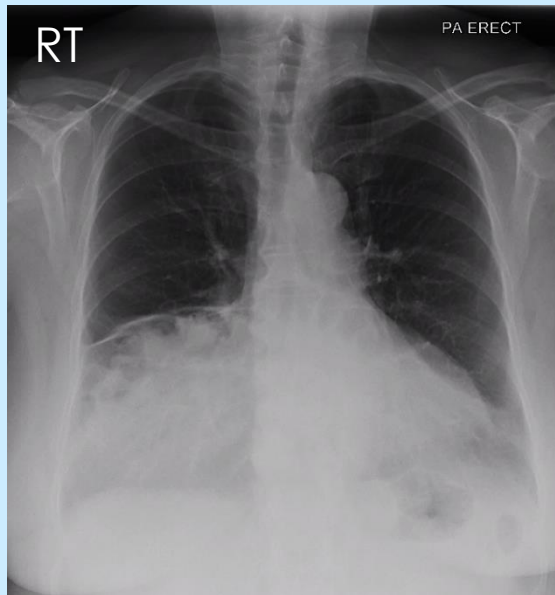


INTERESTING CASE FILES

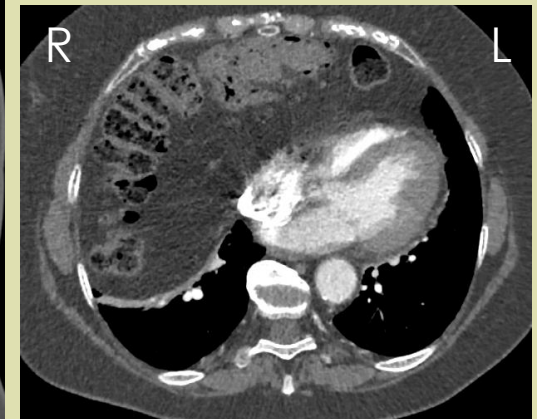
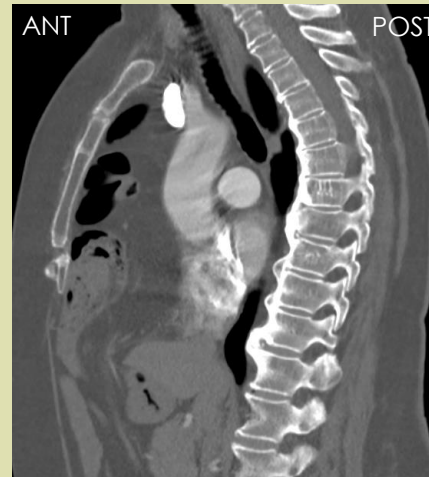 EDITION 3

Test yourself and others!



72y/o female short of breath with cough. Recent long haul flight.
Raised D-Dimer. No previous CXR

Q1: Briefly describe any abnormal findings



Q2: A subsequent CTPA offers more diagnostic clues owing to the abnormal region of the CXR. What can be deduced from these slices? *Note, no PE!*

Q3: What is the term used to describe a scenario where the image review process is prematurely terminated owing to the discovery of an abnormality?

Q4: Are there any further abnormalities visible on the CT?