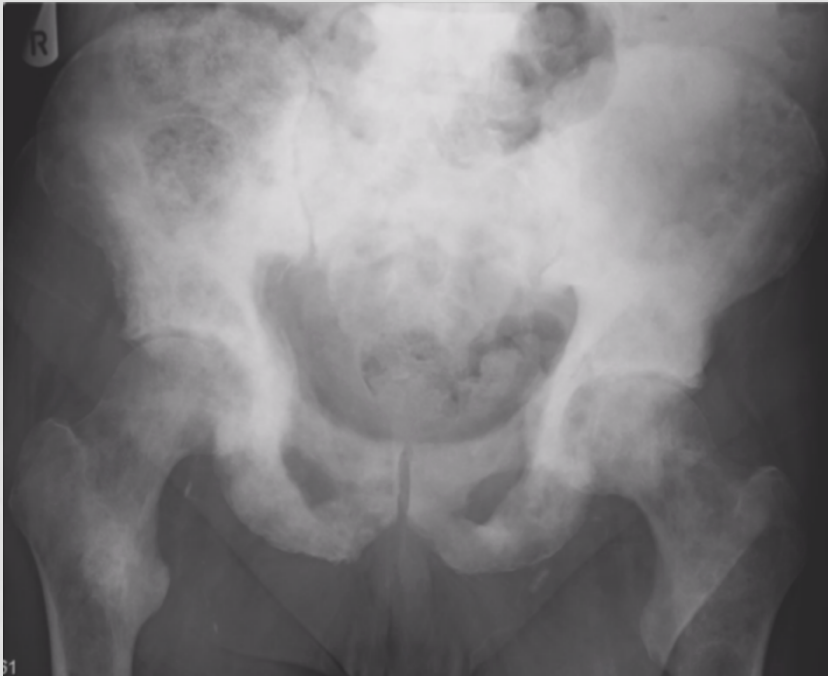


INTERESTING CASE FILES EDITION 1

Test yourself and others!



Q1: Which of these words would you associate with the appearances above?

sclerotic Lytic disseminated
focal
Blastic polyostotic
 Multifocal

Q2: Is this more likely to be a male or female patient and why?

Q3: If this was a GP patient with no previous imaging and you had just performed the x-ray, what would you do next? *TIP: think about your local escalation/alerts*

Q4:

a) The image on the left is current (as is the pelvis XR) and the one on the right is 3yrs old. Has the disease most likely progressed or regressed?

b) A blood test reveals very elevated PSA.

What is this?

What is the most likely diagnosis?

