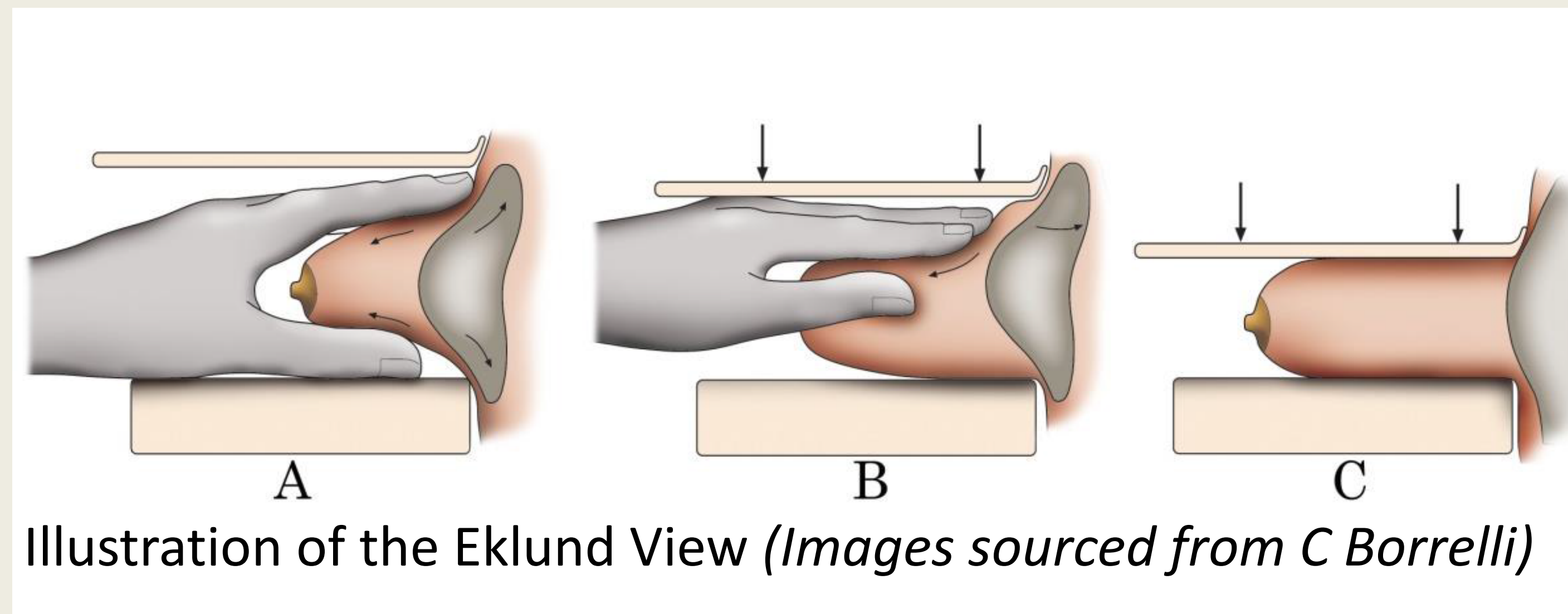


Evaluating the Eklund

recent cases of malignancy illustrating the importance of this additional view of the augmented breast

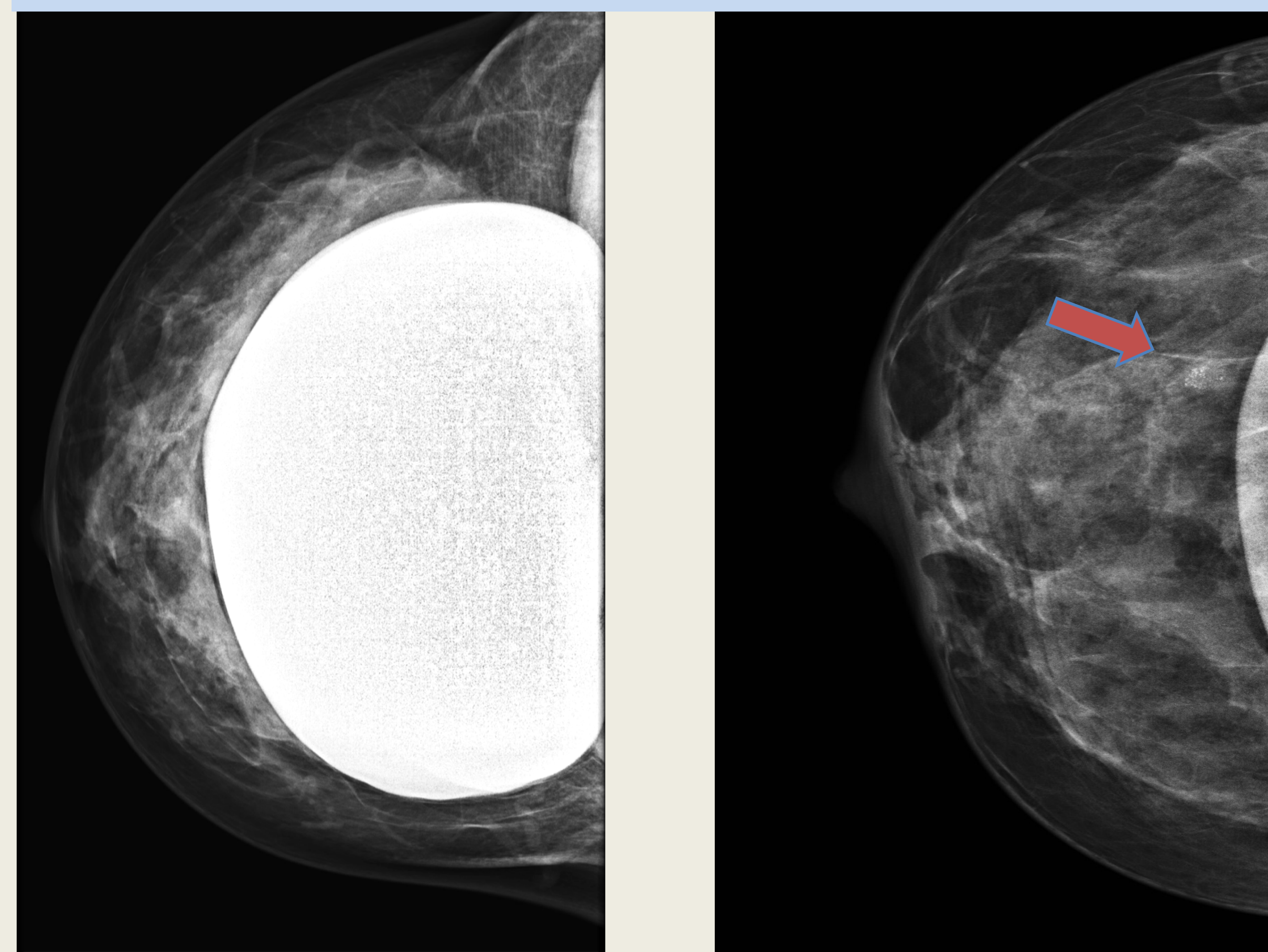
Ann Hills, consultant radiographer



The Eklund technique is mandatory for all women with implants who attend for breast screening, as recommended in the recent publication "NHS Breast screening Programme, Screening women with breast implants" The following 3 cases demonstrate the value of using the Eklund view.

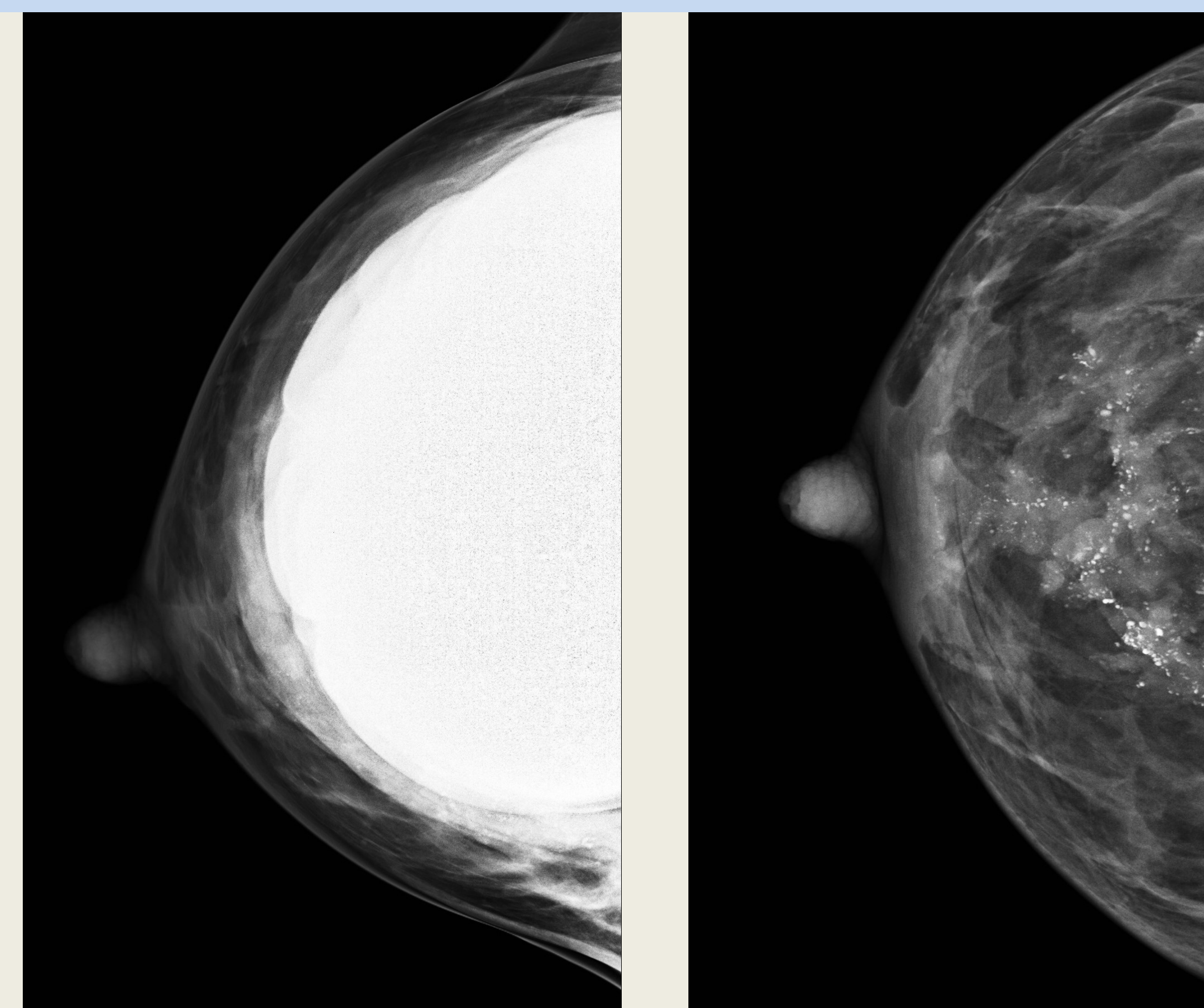
Case 1 screening: A cluster of calcifications not clearly seen on the routine CC view is demonstrated well on the Eklund view.

Diagnosis: ductal carcinoma in situ with grade 1 invasion.



Case 2 symptomatic: No calcifications are seen on the routine CC view. The Eklund view demonstrates the extent of the calcifications.

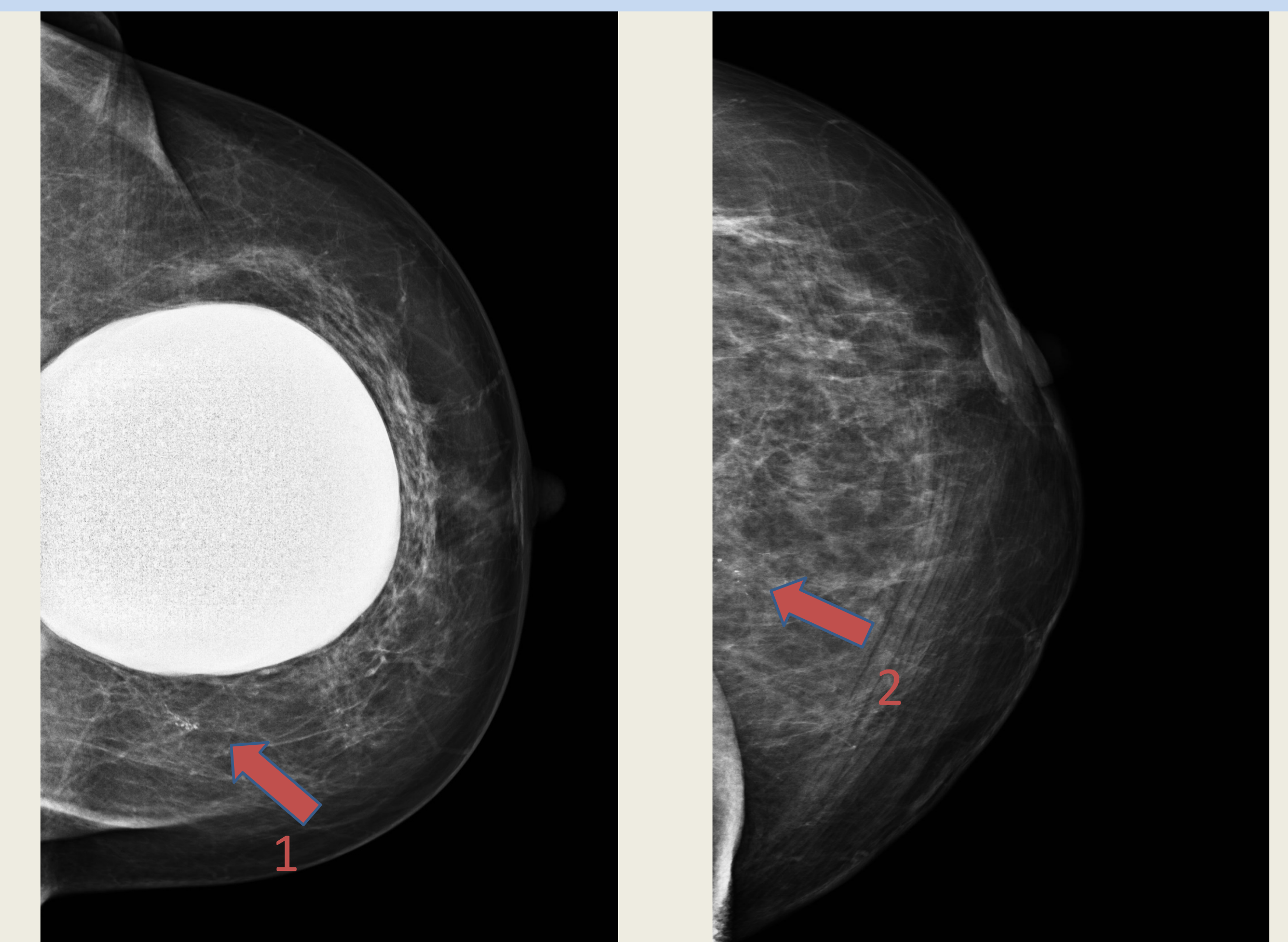
Diagnosis: grade 2 invasive lobular and ductal carcinoma



Case 3 screening: A cluster of calcifications **1** are seen on the routine CC view. The Eklund view helps to identify a second cluster **2** not seen initially.

Diagnosis: **1** = fat necrosis

2 = grade 2 invasive ductal and ductal carcinoma in situ.



Reference

C Borrelli and Z Vegnuti. NHS Breast Screening Programme Screening women with breast implants. Public Health England April 2017